

## Oral Cavity Teratoma in a Neonate

CEO OKONKWO†, AS ALIU††, I EVBUOMWAN\* AND MN GUIRGUIS\*\*

### Summary

Okonkwo CEO, Aliu AS, Evbuomwan I and Guirguis MN. Oral Cavity Teratoma in a Neonate. *Nigerian Journal of Paediatrics*, 1985; 12:95. The occurrence of a huge teratoma in the floor of the mouth of a neonate is reported. The teratoma was excised soon after birth, resulting in an initial good recovery. A rapidly progressive local recurrence of the growth occurred a month later and resulted in the death of the baby. Histology revealed no evidence of malignancy. To our knowledge, this is the first reported case of oral buccal teratoma in a Nigerian newborn infant and one of the few cases in the literature to arise from the floor of the mouth.

### Introduction

TERATOMAS are true tumours present at birth and are classified into two types: one arising from germ cells and the other arising from a group of cells separated from the blastula before differentiation into the three germ layers. The latter group of cells may differentiate to form rudiments of tissues and organs which usually present as a teratoid mass and is attached to any part of the host.<sup>1</sup> This tumour is sometimes, called incomplete conjoined twin.<sup>2</sup> In this communication, we document what we believe to be the first case of oral buccal teratoma in a Nigerian newborn infant.

---

University of Benin Teaching Hospital, Benin City

Department of Surgery (Paediatric Surgery Unit)

†Consultant

††Lecturer/Consultant

\*Lecturer/Consultant

Department of Pathology

\*\*Senior Lecturer/Consultant

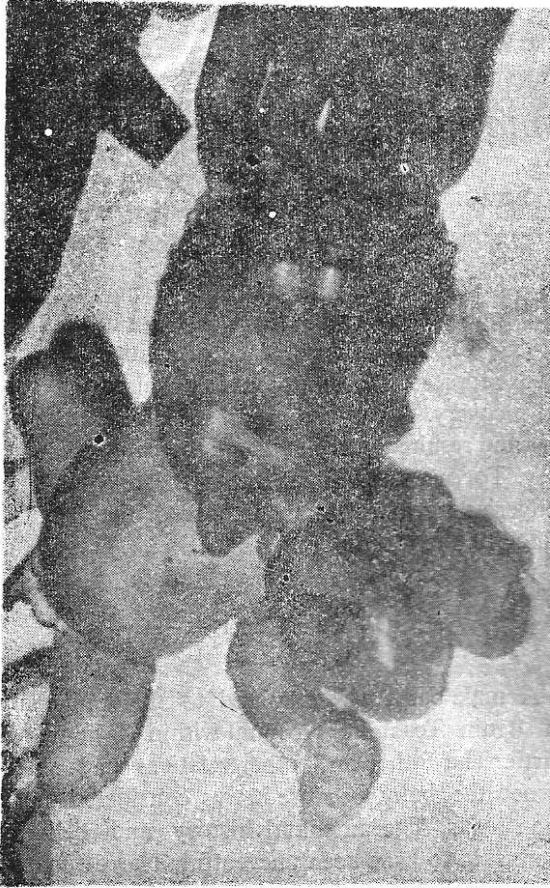---

Correspondence: Dr I Evbuomwan

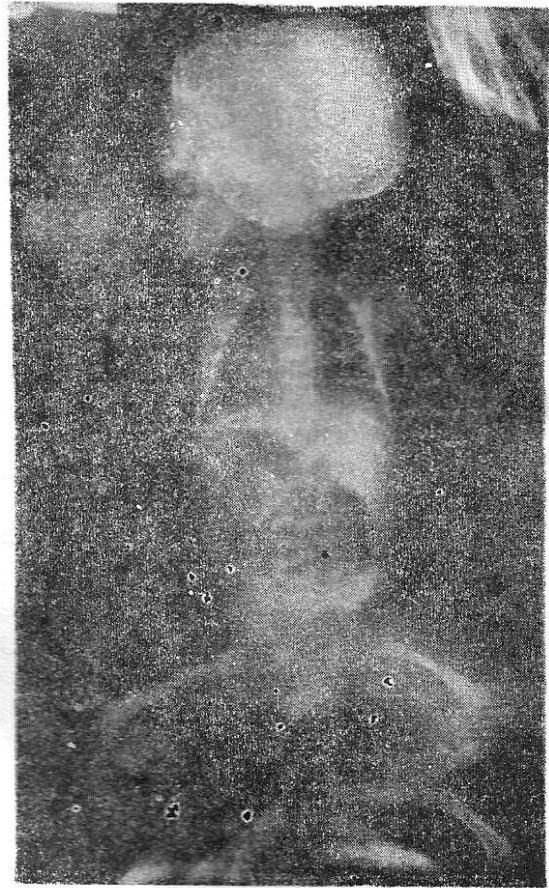### Case Report

A male baby was admitted to the University of Benin Teaching Hospital within 3 hours of birth. The father and other relatives had abandoned the baby because it was considered to be monstrous. The antenatal history and delivery were said to have been uneventful. The estimated gestational age was 39 weeks.

Physical examination revealed a huge mass arising from the floor of the mouth; it was attached to the left edge of the tongue and the left anterior pillar of the fauces (Fig 1). The mass measured 20cm by 15cm and was covered with mature skin. There were macroscopic features recognisable as rudimentary foot, leg and thigh. Radiological evaluation also showed an opacity reminiscent of a long bone (Fig 2). At operation, the mass was excised from its attachment to the edge of the tongue and anterior pillar of the fauces, while the stalk on the floor of the mouth was resected. A portion of the mass which appeared cystic, was located deep in the floor



*Fig. 1* Baby with mass attached to the left lateral edge of the tongue and floor of mouth.



*Fig. 2* X-ray of the baby showing an opacity reminiscent of a long bone, in the upper part of the mass.

of the mouth and complete excision was impossible. The immediate post-operative clinical course was unremarkable.

Four weeks post-operative, the infant developed respiratory distress which was caused by a visible bulge in the submandibular region formed by a rapidly growing mass. Assessment under general anaesthesia revealed that the mass had extended through the whole floor of the mouth and upward along the tonsillar fossa and into the left parotid gland. Partial excision of the mass was carried out in order to relieve the respiratory difficulty. The baby however, died 48 hours later, following aspiration of vomitus.

#### *Pathology*

Gross examination of the specimen revealed a mass approximately 18cm in diameter covered completely by skin. Nipple-like structures, a deformed limb and some digits were identifiable (Fig 3). Section of the mass showed multiple cysts with smooth white lining which contained seromucinous fluid (Fig 4). The deformed limb-like structure contained cartilaginous tissue, but no axial skeleton was found.

The histology showed various tissues arranged in a similar manner to that of the normal foetus. Respiratory epithelium with smooth muscles and nearby cartilagenous tissue were seen (Fig.5).

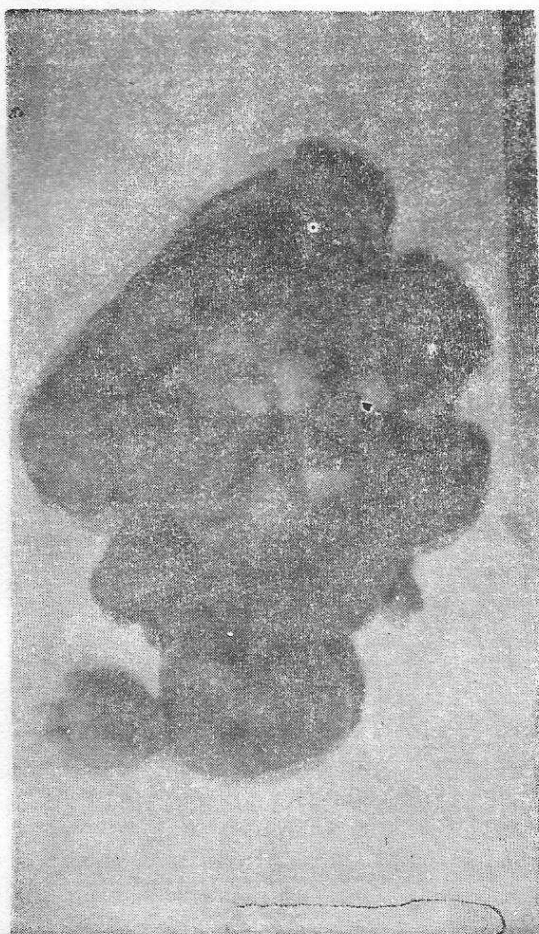

Fig. 3 The mass after it had been removed. Note the rudimentary limb and the nipple like structures.

In other areas, salivary glands and fibro-fatty tissues were detected. Well developed intestinal mucosa (Fig 6) and smooth muscles were present and well-formed skin with its appendages was found in the nipple-like structure; mammary glands were however, absent.

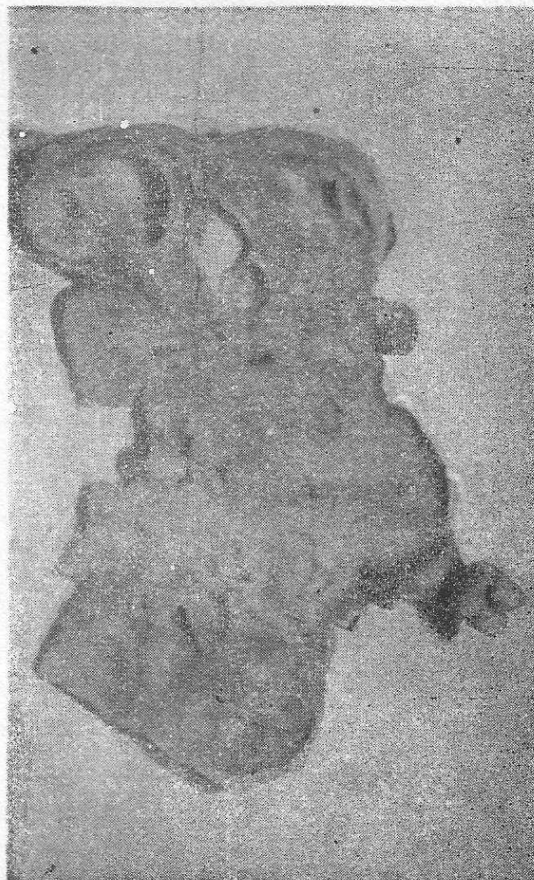


Fig. 4 Cut section of the mass showing multiple cysts of varying sizes.

### Discussion

The literature is scanty on congenital tumours arising from the mouth, although Krafka<sup>3</sup> has drawn attention to the oral cavity in the classification of the sites from which teratoma could arise. Previous reported oral cavity teratomas mostly arose from the roof of the mouth. The term

Nigerian children and also referred to teratomas reported from other centres in Uganda and Rhodesia (now Zimbabwe). There were only two cases of oral cavity teratoma reported from Ibadan. The sites of origin were not specified but the two teratomas were associated with abnormal foetuses, who died soon after birth.<sup>10</sup> To our knowledge, this is the first reported case of teratoma arising from the floor of the mouth in the African infant.

Only a few tumours of the oral cavity have been removed successfully. Most of the cases described in the literature died shortly after birth. The incidence of malignancy associated with oral cavity teratomas is not known. However, malignant degeneration may occur within 4 to 6 months after incomplete removal of the tumour.<sup>11</sup> There was no histological evidence of malignancy in our patient and the recurrence was possibly due to a remnant derived from incomplete excision of the tumour.

#### Acknowledgements

We wish to thank Professor J A Omene for his valuable assistance in preparing the manuscript, the Medical Illustration Unit of the

University of Benin for the photographs and Miss Fidelia Mordi for secretarial help.

#### References

1. Tahilyani NDA and Singh KM. Occipital teratoma bearing digits and nails. *Br J Surg* 1976; **63**: 493.
2. Ashley DJB. Origin of teratomas. *Cancer* 1973; **32**: 390-4.
3. Krafka J. Teratoma: explanation of its cause based on organizer theory of embryology *Arch Pathol* 1936; **21**: 756-64.
4. Enich WE. Teratoid parasites of mouth (episphe-noids, epipalati, (epurani) epignathi). *Am J Orthodontics* 1945; **31**: 650-9.
5. Wilson JW and Gehweiler JA. Teratoma of the face associated with a patent canal extending into the cranial cavity (Rathke's pouch) in a three-week old child. *J Pediat Surg* 1970; **5**: 349-59.
6. Tsingoglou ST. Unusual tumours of the oral cavity in newborn. *Ann Clin Paed Univ Atheniensis*. 1970; **17**: 210-5.
7. Miller AP and Owens JB. Teratoma of the tongue. *Cancer* 1966; **19**: 1583-6.
8. Bras G, Butts D and Hoyte DA. Gliomatous teratoma of the tongue: Report of a Case. *Cancer* 1969, **24**: 1045-50.
9. Mabogunje OA, Nirodi NS, Lawrie JH and Edington GM. Teratomas in Nigerian children. *East Afr Med J* 1980; **57**: 461-9.
10. Williams AO, Lagundoye SB and Bankole MA. Sacrococcygeal teratoma in Nigerian children. *Arch Dis Child* 1970; **45**: 110-3.
11. Hatzihaberis F, Stamatis D and Staurinos D. Giant epignathus. *J Pediat Surg* 1978; **13**: 517-8.

Accepted 20 May 1985

