

Akinyinka OO
Adepoju, AA
Ashubu OF
Ogunbosi BO
Olatunji RB
Akere A
Orimadegun, AE
Oluwasola AO

CC –BY

Ulcerative colitis in Nigerian children: A report of two cases and review of the literature

DOI:<http://dx.doi.org/10.4314/njp.v46i4.8>

Accepted: 4th October 2019

Akinyinka OO (✉)
 Adepoju, AA, Ashubu OF
 Ogunbosi BO
 Department of Paediatrics,
 College of Medicine, University of
 Ibadan/University College Hospital
 Ibadan
 Email: asegun@hotmail.com

Olatunji RB
 Departments of Radiology

Akere A
 Departments of Medicine

Orimadegun AE
 Institute of Child Health,

Oluwasola AO
 Departments of Pathology,
 College of Medicine, University of
 Ibadan / University College
 Hospital, Ibadan, Nigeria.

Abstract: Ulcerative colitis (UC) is a relapsing, idiopathic chronic inflammatory disorder of colon characterised by ulcerations of the colon with bleeding, mucosal crypt abscesses and inflammatory pseudo polyps associated with abdominal pain with tenesmus and significant weight loss. Ulcerative colitis has rarely been reported in sub-Saharan African children. In this report we present 2 cases of ulcerative colitis in

Nigerian children confirmed by barium enema, colonoscopy and histology. A review of the current literature on ulcerative colitis is also discussed.

Key Words: Ulcerative Colitis, Inflammatory, Pseudopolyps, Colonoscopy.

Introduction

Inflammatory bowel disease (IBD) are a heterogenous group of diseases resulting from a complex interplay of host factors,^{1,2} microbial factors³ and environmental factors.^{4,5} This group of diseases, classified into Crohn's disease (CD) and ulcerative colitis (UC) is characterised by chronic and relapsing inflammation of the gastrointestinal tract.⁶ Ulcerative Colitis (UC) which is the rarer form of IBD, is characterised by recurring inflammation of the mucosal layer of the large intestine extending continuously upwards from rectum. An estimated prevalence of 2-19.7/100,000 children has been reported in Caucasian children but less frequently reported in other ethno-racial groups.^{7,8} Though UC is rarely reported in black African children and was considered non-existent in Nigerian children prior to a report in 2012,⁹ however recent literature indicate increasing reports of childhood UC in developed and some developing countries,¹⁰⁻¹² including Nigeria.¹³⁻¹⁵ Therefore it is necessary for UC to be considered in the differential diagnosis of

children with clinical symptoms of recurrent abdominal pain, tenesmus, loose bloody stools and weight loss in order to make early diagnosis and commence appropriate therapy in order to reduce associated long-term morbidity and mortality as well as cost of care. This report presents the clinical, imaging, histology and laboratory profiles of 2 cases in Nigerian children and discusses UC in order to underscore the changing face of IBD in Africa.

Case I

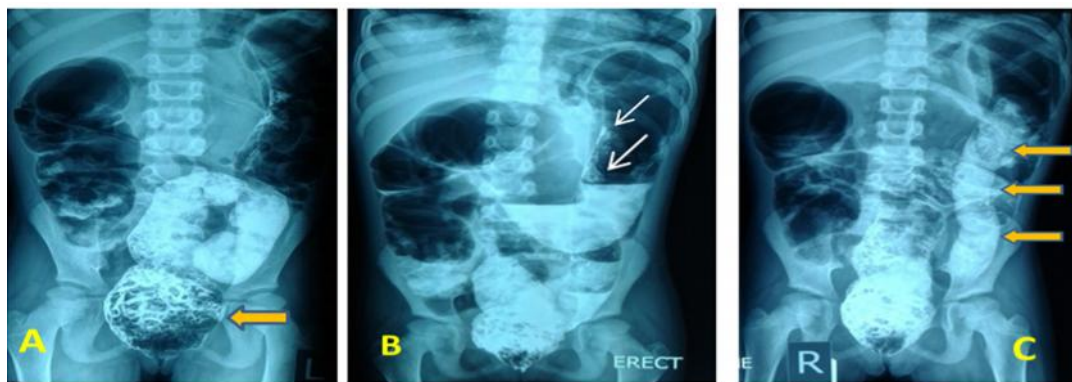
A 10-year-old Nigerian girl presented at the Children's Outpatient Clinic of the University College Hospital (UCH), Ibadan, Nigeria with a 5-year history of recurrent 3 to 5 bloody loose stools daily which occasionally consisted of undigested food particles. Each episode of diarrhoea lasted averagely 2-4 weeks with the last episode of loose stools occurring 2 weeks prior to presentation. There has been progressive weight loss of 5 years duration despite good appetite and a 2 year history of

body swelling which subsides occasionally. She was brought in unconscious and had had afebrile multiple convulsions a day before presentation at the UCH, Ibadan. Patient had been managed as a case of protein losing enteropathy at another health facility for about 4 years without improvement and was referred to the UCH when she became unconscious. Patient is the first of 3 children and no history of similar illness or convulsions in any other member of the family.

Examination showed an unconscious child with a Glasgow Coma Score of 7, afebrile, in respiratory distress with a weight of 14.7kg (Z-score <-3 SD for age), height 127cm (Z-score <-2SD for age) and mid upper arm circumference of 11.5cm. She had generalised lymphadenopathy with flexural hyperpigmented skin lesions and bilateral pitting oedema up to the knees. Ankle clonus was sustained bilaterally and fundoscopy was normal. Patient had dull percussion notes over the right lower lung zone and a non-tender hepatomegaly of 9cm. Digital rectal examination revealed polypoid protrusion through the anus with multiple polyps in the rectum.

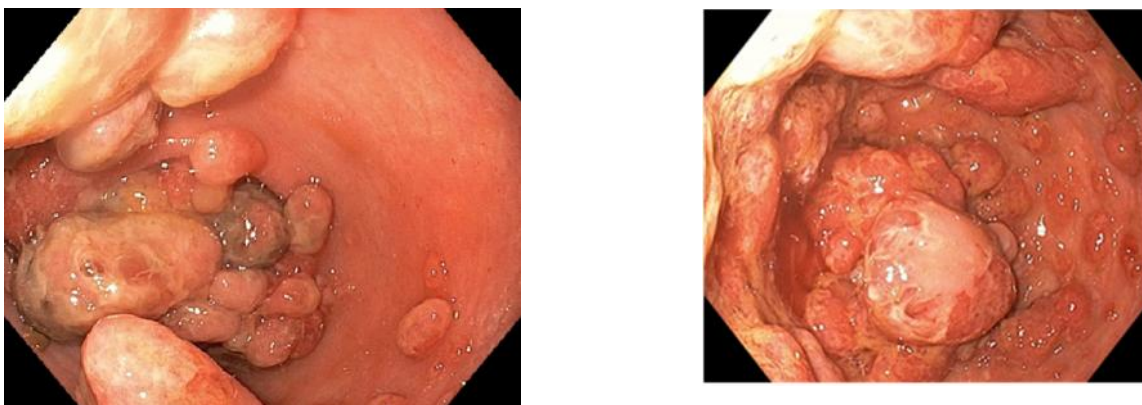
Investigations at admission revealed haematocrit of 29%; white blood cell count of $15,250\text{cells}/\text{mm}^3$, neutrophils of 76%, lymphocyte- 19% and platelets of $242,000/\text{mm}^3$. Serum Sodium 126mmol/l, Potassium 2.5mmol/l, Chloride 91mmol/l, Sodium bicarbonate 20mmol/l, Calcium 7.3mg/dl, Phosphate 3.0mg/dl, Urea 49mg/dl and Creatinine 1.2mg/dl. Alkaline phosphatase 169IU/l, aspartate aminotransferase 92IU/l, alanine aminotransferase 109IU/l, gamma glutamyl transpeptidase 213IU/l, total serum protein 3.4g/dl with albumin of 1.0g/dl and INR of 1.8. Blood culture yielded no growth after 4 days of incubation. Chest X-ray confirmed consolidation in the right middle and lower lung zones and abdominal ultrasound showed hepatomegaly with mild left hydronephrosis. Barium enema revealed florid polyps in the recto-sigmoid colon, filiform polyps in the descending colon, poorly distensible descending colon with lack of haustral markings which gave the lead-pipe appearance of the colon and a normal proximal colon (Fig 1).

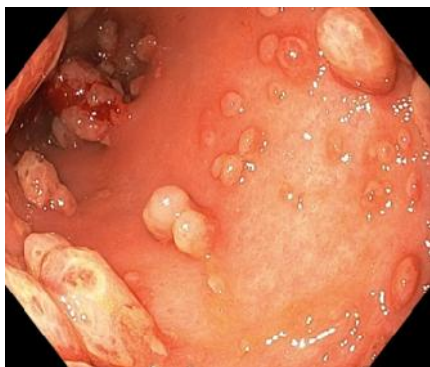Fig 1: Double contrast barium enema shows multiple polypoid filling defects in rectum (block arrow in A), filiform polyps (white arrows in B) and lead pipe appearance of descending colon (black arrows in C)



Colonoscopy done on 20th day of admission showed grossly distorted anatomy of the colon, inflamed mucosa and multiple polypoid lesions, worst in the rectum, some of the lesions are hyperaemic with some areas of necrosis. The anatomy of the caecum is distorted making it difficult to visualise the ileal and appendiceal orifices. (Fig 2)

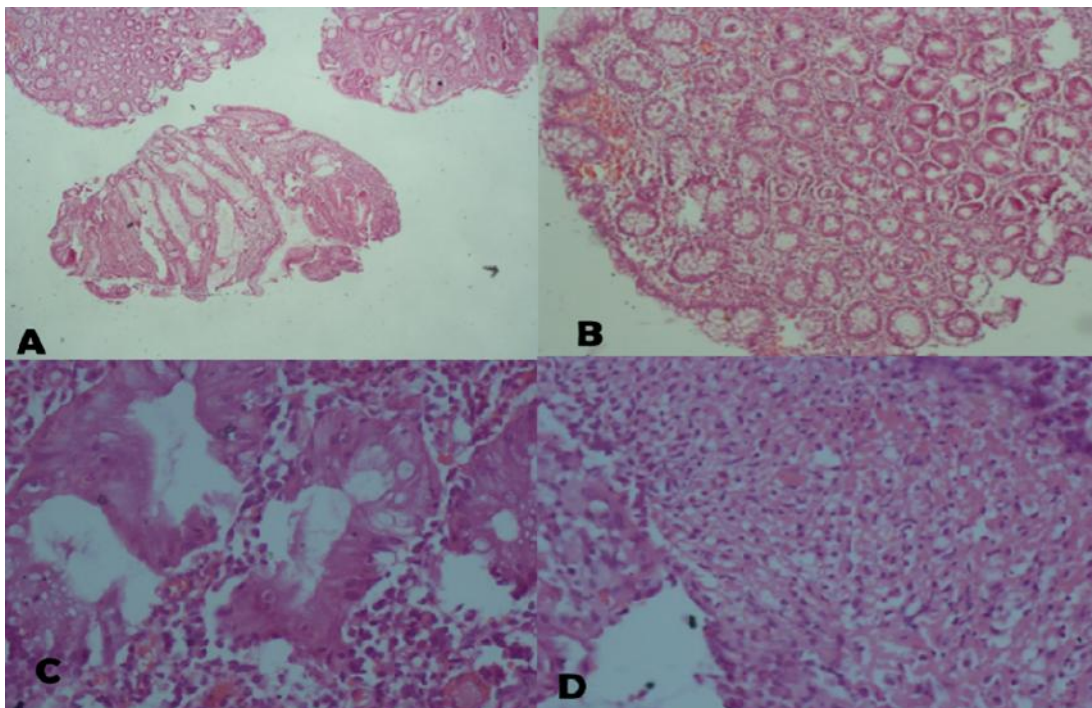
Fig 2: Endoscopic findings of segments of the colon with multiple polyps with hyperaemia and necrosis.





Histology of the colonic lesion showed polypoid fragments of tissue with intense neutrophil polymorphs infiltration of the lamina propria, lymphocytes, plasma cells and eosinophils and focal lymphoid aggregates. There is glandular proliferation with nuclear crowding and loss of epithelial mucin. These features were consistent with Ulcerative colitis (Figure 3).

Fig 3: Histology of the colonic tissue biopsy: A (x40) and B (x100) show intensely inflamed lamina propria. C (x400) show loss of epithelia mucin and D (x100) show intense necrosis noted in some of the sections of the biopsy.



On admission, patient was commenced on intravenous Rocephin® for 7 days and was transfused daily with fresh frozen plasma for seven days and with fresh whole blood on the 8th and 18th day of admission on account of PCV of 16% and 17% respectively.

Patient was placed on exclusive enteral nutrition with high protein and high fibre diet. Diarrhoea subsided after 2 weeks and oedema completely resolved after 4 weeks of admission. She was thereafter commenced on Sulfasalazine (5-Aminosalicylic Acid) at a dose of 20mg/kg with good response.

Repeat liver function tests on day 16 showed alkaline phosphatase 534 IU/l, aspartate aminotransferase 31 IU/l, Alanine aminotransferase 21 IU/l, gamma glutamyl transpeptidase 520 IU/l, total protein 4.2g/dl, Albumin 1.8g/dl and all parameters had been normal subsequently. She was discharged home after 29 days of hospitalisation with a weight of 15kg. She had been seen on outpatient follow-up with weight of 25kg, mid upper arm circumference of 14.3cm and height of 131cm at 2 months after hospital discharge and no relapse of symptoms.

Case II

A 3-year-old male child presented at 7 months of age with a 3 month history of recurrent passage of loose bloody stools averaging 6 motions per day. Mother had managed the child at home with oral rehydration salts solution, some over the counter drugs and at different private health facilities with no significant improvement. Episodes of loose bloody stools were often associated with fever and abdominal discomfort and cries before and during stooling which resolved spontaneously with resolution of bowel symptoms. There was history of poor appetite and poor weight gain as well as history of joint pains and swellings affecting the knees and ankles. No history of similar illness in the immediate or extended family.

On examination, child looked chronically ill, small for age weight 5.67kg (< 0.4th centile), length 64cm (0.4th centile) and MUAC 10.5cm, pale, with a temperature of 39°Celsius. There was no peripheral oedema and systems examination.

An initial diagnosis of dysentery was made and patient was commenced on a 10-day course of oral cotrimoxazole without resolution of gastrointestinal symptoms.

Full blood count showed white cell count 39,230/mm³, packed cell volume 22% and thrombocytosis of 2.8 million/mm³. Peripheral blood film revealed microcytic hypochromic anaemia. C-reactive protein and Erythrocyte Sedimentation Rate were 11U/L and 48mm/hr. (NR 0-14mm/hr.) respectively. Stool microscopy, skin prick test, serum IgE, serum electrolytes and liver function tests were normal. Serum Iron 3.5µmol/L (NR 5.83-34.5µmol/L), serum transferrin 63.8µmol/L (NR 26.0-47.0µmol/L), transferrin percentage saturation 2.7% (NR 20.0-55.0%) and serum ferritin 7ng/mL (NR 15-120ng/mL).

Colonoscopy showed widespread mucosal erosions with deep ulcers seen in some areas with slightly raised edges. Histology showed severe infiltration of the lamina propria by chronic inflammatory cells mainly lymphocytes and plasma cells. The glands were lined by a layer of tall columnar epithelium with abundant goblet cells. No malignant change, granuloma or crypt abscesses seen. Barium enema and faecal calprotectin could not be done due to financial constraints.

Patient was commenced on iron supplement, oral prednisolone 1mg/kg/day and oral sulphasalazine which was optimised to 20mg/kg/day. Patient's symptoms improved within 5days of starting treatment. He had been admitted once since diagnosis due to a flare of the disease and severe anaemia for which he was transfused. He has been relatively asymptomatic on follow up in the past 12months and he is growing well; weight 14kg (50th centile) and height 94cm (>9th centile).

Discussion

The diagnosis of UC in these two patients was confirmed by endoscopy and histology. Ulcerative Colitis generally runs a mild course and responds well to therapy; however, severe complications can arise as the disease progresses. The mean time to diagnosis of UC from onset of symptoms elsewhere is around 3 months^[16] and this fact is poignantly illustrated by the delay of 5 years from onset of diarrhoeal illness in the index case till first presentation in our institution where correct diagnosis of UC was promptly made because of a high index of suspicion and the availability of diagnostic facilities in the UCH, however, the second case reported in this review, the time to diagnosis was shorter probably because of a higher index of suspicion elicited by the first case. In one adult Nigerian case series, it took a range of 2 -7 years for the diagnosis to be made from onset of symptoms.^{17,18} Senbanjo *et al*⁹ rightly advocated heightened clinical suspicion in clinical evaluation of childhood diarrhoeal illnesses in UC naïve regions for optimisation of diagnosis of UC.⁹ Ulcerative colitis is associated with an increased risk of colorectal cancer and primary sclerosing cholangitis with onset of UC at a young age been considered a specific risk factor for CRC.¹⁸ It is advocated that children with disease onset in the first decade of life should undergo annual colonoscopic screening

and biopsy for dysplasia beginning in adolescence which unfortunately in Nigeria is poorly developed.¹³

The paucity of reported cases of childhood IBD and UC in African children may be associated with poor diagnostic facilities¹⁴ and non-consideration of UC as a differential diagnosis. According to Day and Lemberg, the diagnosis of paediatric UC relies primarily on the consideration of the diagnosis¹⁹ and the failure to include UC in the differential diagnostic considerations of childhood diarrhoeal illnesses is a critical misstep toward erroneous diagnosis. In Africa, several other disease entities may mimic UC including infectious colitis²⁰ and Henoch-Schonlein Purpura²⁰ resulting in under-reporting.

The typical epidemiological profile of paediatric UC is that of a multifactorial, genetically predisposed, peri-adolescent Caucasian male child in a temperate environment¹¹ with altered intestinal immune response²¹ which contrasts with the profile of the patients in this report. There was no known family history of similar illness in these two cases who reside in suburban tropical environment concordant with the previously reported case in Nigeria.⁹ It is known that children suffer more extensive UC disease than adults even when diagnosis is timely.²² All the clinical, serologic and imaging markers of severe disease were present in these cases ostensibly accentuated by delayed diagnosis. Five of the six critical variables in the Paediatric Ulcerative Colitis Activity Index (PUCAI)²³ a reliable clinical marker, were identified in these two cases. These include abdominal pain, high frequency loose stools, 3-5 stools per day, rectal bleeding and interruption of normal activities. (PUCAI score 50; moderate disease). Likewise, the main serological markers of inflammation were identified in one of these two cases. Severe hypoalbuminemia, presumably taken in isolation and probably a reason for the nebulous label of protein-losing enteropathy at the source of referral, is one of the four main but non-specific serum markers of inflammation namely elevated ESR, CRP, platelet, and low albumin. The specific faecal markers of gut inflammation such as faecal alpha-1-antitrypsin, calprotectin, S100A12, and lactoferrin were not tested for as they are not available in our centre.¹⁹

Barium enema demonstrated left sided colitis up to the splenic flexure compatible with the E2 type of UC according to the Paris classification.²⁴ Lead pipe appearance of the colon, as evident in this patient, is seen in long-standing cases of UC on barium enema and represents concentric narrowing with rigidity of the involved colonic segment.²⁴ Colonoscopy is the gold standard in visual evaluation of disease extent and it revealed significant alterations of the colonic mucosal pattern, ulcers and remarkable pseudopolyps in our patient.

Both UC and CD can present with extraintestinal manifestations (EIM). The skin, joints, eyes and lungs may be involved in the relapsing-remitting inflammatory process characteristic of chronic IBD but occur more with CD. Growth failure was part of the presentation in these patients and may count for either an EIM or a

natural sequel of malnutrition in IBD. Right sided pneumonic consolidation was present at diagnosis of UC in one of the cases. It is however unclear whether the pulmonary pathology is related to the IBD or just an isolated finding. The same can be said of the hyperpigmentation at the joints of the patient, although no associated pain or swelling. There are few reports of EIM in paediatric UC from low prevalence regions but none of these were pulmonary or cutaneous.²⁵ There was no feature suggestive of EIM in the case reported by Senbanjo *et al* in Lagos, Nigeria.⁹

The management modalities for UC include nutritional management which aims to treat deficiencies and reduce inflammation, pharmacological treatment such as Aminosalicylic Acid, corticosteroid, immunomodulators, antibiotics and biological drugs as well as surgical management especially when medical management fails. Both patients had exclusive enteral nutrition with high protein and high fibre diet to induce remission and placed on Sulfasalazine (5-Aminosalicylic Acid) with good response. Management of illnesses are mainly out

of pocket in Nigeria, therefore limiting the use of more effective modalities including biologics which are not usually affordable.

These cases highlight the importance of multidisciplinary care of patients as more cases may be diagnosed in the near future as part of the observed epidemiological transition in regions hitherto known with low prevalence, the need for a dedicated multidisciplinary team cannot be overemphasised for optimal management and improved treatment outcomes.

Conclusion

Several cases of UC are now being reported in Nigeria and there is therefore the need for concerted multidisciplinary approach in the evaluation of abdominal pain with chronic and bloody diarrhoea in Nigerian children. With the increasing reports of UC, there is the need for the development of an active paediatric gastroenterology service.

References

- Huang, H., Fine-mapping inflammatory bowel disease loci to single variant resolution. *Nature*, 2017. 547: p. 173-178.
- Knights, D., Complex host genetics influence the microbiome in inflammatory bowel disease. *Genome Med*, 2014. 6: p. 107.
- Morgan, X., Dysfunction of the intestinal microbiome in inflammatory bowel disease and treatment. *Genome Biol.*, 2012. 13: p. R79.
- Ananthakrishnan, A., Environmental risk factors for inflammatory bowel diseases: a review. *Dig. Dis. Sci*, 2015. 60: p. 290-298.
- Halfvarson, J., Dynamics of the human gut microbiome in inflammatory bowel disease. *Nat. Microbiol.*, 2017. 2: p. 17004.
- Grossman, A. and R. Baldassano, Ulcerative colitis. Nelson textbook of paediatrics. 20th ed. 2016, Philadelphia: Elsevier. 13.
- Henderson, P., et al., Rising incidence of pediatric inflammatory bowel disease in Scotland. *Inflamm Bowel Dis*, 2011. 10: p. 1002.
- Benchimol, E., et al., Increasing incidence of paediatric inflammatory bowel disease in Ontario, Canada: evidence from health administrative data. *Gut*, 2009. 58: p. 1490-1497.
- Senbanjo, I., et al., Ulcerative colitis in a Nigerian girl: A case report BMC research notes, 2012. 5: p. 564.
- Benchimol, E., et al., Epidemiology of pediatric inflammatory bowel disease: a systematic review of international trends. *Inflamm Bowel Dis*, 2011. 17: p. 423-439.
- M'Koma, A., Inflammatory Bowel Disease: An Expanding Global Health Problem. Clinical Medicine Insights: *Gastroenterology.*, 2013. 6: p. 33-47.
- Rukunuzzaman, M. and A. Karim, Ulcerative colitis in infancy. *Saudi J Gastroenterol*, 2011. 17: p. 414-417.
- Senbanjo, I., et al., Inflammatory bowel disease in Nigerian children: case series and management challenges, Paediatrics and International Child Health. Paediatrics and International Child Health, 2019. 10.
- Ekanem, E., et al., Ulcerative colitis in a Nigerian child: case report. *Niger J Paediatr*, 2016. 43(4): p. 291-294.
- Ewah-Odiase, R., et al., Ulcerative colitis in a Nigerian child: a case report. *Int J Gastroenterol Hepatol Transpl Nutr* 2016. 1(3): p. 29-31.
- Lee, D.-w., et al., Diagnostic delay in inflammatory bowel disease increases the risk of intestinal surgery. *World J Gastroenterol*, 2017. 23(35): p. 6474-6481.
- Kugathasan, S., et al., Epidemiologic and clinical characteristics of children with newly diagnosed inflammatory bowel disease in Wisconsin: a state wide population-based study. *J Pediatr*, 2003. 143: p. 525-531.
- Ekwunife, C., et al., Ulcerative Colitis Prone to Delayed Diagnosis in a Nigerian population: Case Series. *Ann Med Health Sci Res*, 2015. 5: p. 311-313.
- Day, A. and D. Lemberg, Ulcerative Colitis in Children and Adolescents. In: Mortimer O'Connor (ed). Ulcerative Colitis- Treatments, Special Populations and the Future Intech, 2011.

20. Siow, V., R. Bhatt, and K. Mollen, Management of acute severe ulcerative colitis in children. *Semin pediatr Surg*, 2017. 26(6): p. 367-372.
21. Hugot, J. and M. Bellaiche, IBD: The pediatric gastroenterologist's perspective. *Pediatr Radiol*, 2007. 37: p. 1065-1070.
22. Limbergen, JV, et al., Definition of phenotypic characteristics of childhood-onset inflammatory bowel disease. *Gastroenterology*, 2008. 135: p. 1114-1122.
23. Turner, D., et al., Pediatric IBD Collaborative Research Group. Appraisal of the Pediatric Ulcerative colitis activity index (PUCAI). *Inflamm Bowel Dis*, 2009. 15: p. 1218-1223.
24. Levine, A., et al., Pediatric modification of the Montreal classification for inflammatory bowel disease: the Paris classification. *Inflamm Bowel Dis*, 2011. 7: p. 1314-1321.
25. Levine, J. and R. Burakoff, Extraintestinal Manifestations of Inflammatory Bowel Disease. *Gastroenterol Hepat*, 2011. 7(4): p. 235-241.