

Kartagener's Syndrome in a Child: a Six-year Follow-up

H Ahmed* K Alhassan** AO Amole⁺

Summary

Ahmed H, Alhassan K, Amole AO. **Kartagener's Syndrome in a Child: a Six-year Follow-up.** *Nigerian Journal of Paediatrics* 1997; 24: 24 A four-year old boy with Kartagener's syndrome is reported because of its rarity and being the first case to our knowledge, to be documented in Nigeria. There was situs inversus with visceratrial concordance. During a six-year follow up, the child was admitted only twice to the hospital as a result of recurrent sinopulmonary infections. He continued to do well with no radiological evidence of progression of the bronchiectasis on regular chest physiotherapy and antibiotics, given during periods of exacerbation of the respiratory infections. Growth monitoring over a period of six years from age 4 years in 1990 to age 10 years in 1996 however, showed that the child's weight was on or below the 5th percentile and the height oscillated around the 25 percentile on the National Center for Health Statistics (NCHS) charts. Prompt and adequate chest physiotherapy and administration of antibiotics are essential to prevent progression of bronchiectasis in Kartagener's syndrome.

Introduction

THE triad of situs inversus totalis, paranasal sinusitis and bronchiectasis, first described in 1933 by Kartagener,¹ has since been termed

Usmanu Danfodiyo University Teaching Hospital,
Sokoto

Department of Paediatrics

* Senior Lecturer

Specialist Hospital, Sokoto

Department of Paediatrics

** Senior Medical Officer

University of Ilorin Teaching Hospital

Department of Radiology

+ Lecturer

Correspondence: Hamidu Ahmed

Kartagener's syndrome; it occurs typically in individuals with mirror image dextrocardia and functionally normal hearts. Logan, Abott and Hatcher² have reported that bronchiectasis occurs in as many as 25 percent of patients with situs inversus, but probably in less than 0.5 percent of the general populations. Several workers³⁻⁵ have explained the development of bronchiectasis in the syndrome on the basis of the immotility of defective respiratory cilia; indeed, about 50 percent of patients with ciliary defects actually have the classical Kartagener's syndrome.⁶ However, it is now accepted that the syndrome is a rare autosomal recessive condition with incomplete penetrance occurring in 1:15,000 births.⁷ The present communication which concerns a four-year old child with Kartagener's syndrome is

reported because, to our knowledge, it is the first case to be documented in Nigeria and also because of its rarity.

Case Report

SY, a four-year old male child was first admitted to the Specialist Hospital, Sokoto (SHS), in July 1990 with one-week history of fever, breathlessness, mucopurulent nasal discharge and cough productive of mucopurulent, foul-smelling and occasionally, blood-stained sputum. He was a product of normal pregnancy, full term and spontaneous vaginal delivery. Birthweight was 3.2kg and the neonatal period was normal. He received BCG vaccination soon after birth, followed on schedule by other vaccinations in the expanded programme of immunization (EPI).

Significant past medical history included frequent and recurrent attacks of cough with or without fever and mucopurulent nasal discharge with an onset at the age of about two years. These attacks which were successfully treated with antibiotics for short periods of five to seven days, were never before associated with such severe breathlessness to warrant admission into hospital. Family history revealed that the father and mother were first cousins. The parents were alive and well; the father was a well - educated senior civil servant with a second wife. There were four siblings of the patient, who was the third in rank. These siblings were alive and well. The second wife had two children who were also alive and well.

Physical examination revealed an ill-looking but fully alert child with dyspnoea, tachypnoea and mild pallor. He was febrile with an axil-

lary temperature of 39°C; the pulse (rate 120 beats /min) was of good volume and regular. The weight was 14kg being between the 5th and 10th percentiles on the USA National Center for Health Statistics (NCHS) growth chart.⁸ The mid-upper arm circumference was 14cm. There was mucopurulent nasal discharge, halitosis and localized tenderness over the maxillae; the ears and throat were normal. He had moderate digital clubbing. There was no cardiac enlargement with the apex beat (AB) located in the 5th right intercostal space in the mid-clavicular line. The jugular venous pressure was not raised. The heart sounds were

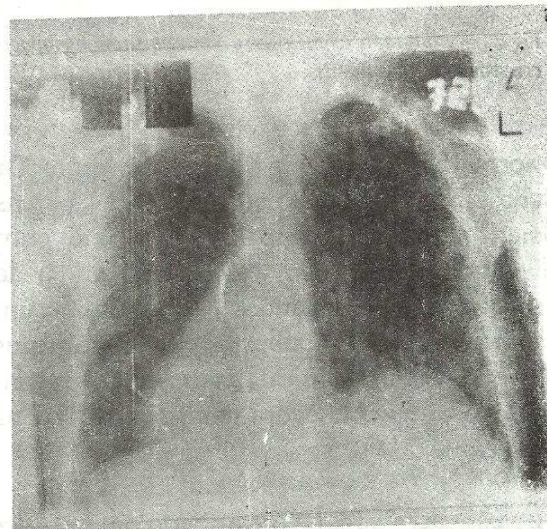


Fig 1 Initial chest radiograph of the patient at the age of four years (July 1990). Note the dextrocardia and situs inversus. Note the liver shadow on the left and stomach air bubble on the right, the bronchial dilatations as indicated by 'tram-line' appearance on the left side and bilateral patchy pulmonary opacities consistent with bronchiectasis and inflammation.

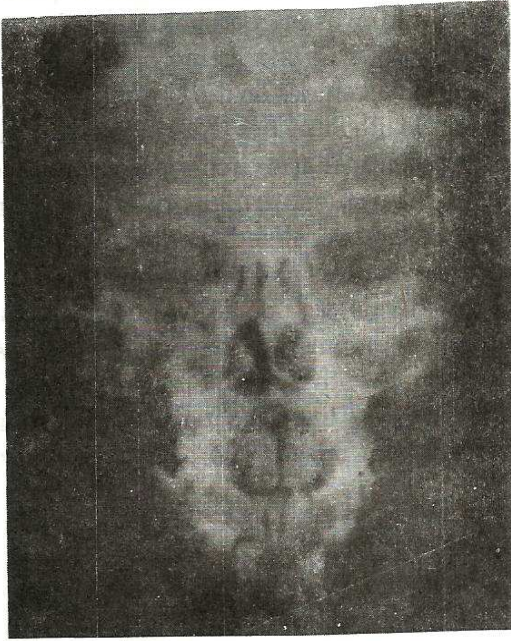


Fig 2 Radiograph of maxillary sinuses showing opacity consistent with sinusitis.

normal and there were no heart murmurs. The chest movement was equal bilaterally; percussions note was not impaired and the air entry was normal, but there were bilateral and widespread coarse crepitations. Abdominal examination revealed no abnormal physical signs. The provisional clinical diagnosis consisted of dextrocardia, bronchopneumonia and chronic sinusitis.

Investigations that were undertaken included a chest radiograph which confirmed the dextrocardia with the aorta on the right and situs inversus (Fig 1). The heart size was normal with cardiothoracic ratio of 0.5. There were obvious bronchial dilatations, as evidenced by "tram-line" appearances which were more prominent on the left. There were also bilat-

eral patchy basal pulmonary opacities. Ultrasonography of the abdomen confirmed situs inversus with a normal liver and biliary system situated on the left side of the stomach and a small spleen on the right side. Plain radiographs of the paranasal sinuses showed completely radio-opaque maxillary sinuses (Fig 2), a picture that was consistent with sinusitis. Electrocardiography revealed an inverted P wave in limb lead I and deep Q waves in chest leads V_1, V_2 and AVL, findings that were consistent with dextrocardia and normally-related great arteries. Other investigations revealed haemoglobin (Hb) 9.0g/dl, total white cell count $6.8 \times 10^9/L$ (neutrophils 64 percent, lymphocytes 26 percent, monocytes 8 percent, eosinophils 2 percent), reticulocytes 3.2 percent, platelets $120 \times 10^9/L$. Hb genotype was AA. Malaria parasites were not seen on a blood film, blood cultures were negative while stool and urinalysis were normal. Examination of the sputum and gastric washings on three occasions revealed no acid-fast bacilli. Culture of the sputum grew mixed flora of *Streptococcus pneumoniae* and *Haemophilus influenzae* both of which were sensitive to ampicillin and chloramphenicol.

On the basis of the above findings, particularly the dextrocardia with situs inversus totalis, paranasal sinusitis and bronchiectasis, the final diagnosis was Kartagener's syndrome and bronchopneumonia. Initial treatment for the infection was with intravenous ampicillin combined with cloxacillin (*Ampiclox*) for five days, after which the *Ampiclox* was replaced with oral ampicillin when sputum culture yielded organisms that were sensitive to ampicillin. Oral antibiotic therapy was continued for five more days with marked improvement in the respiratory signs and subsidence of the fever.

On the third day of admission, aspiration of the maxillary sinuses was performed and about 15ml of mucopurulent material evacuated; culture of this aspirate was however, not carried out. In addition to the above management, the patient underwent daily physiotherapy, consisting mainly of postural drainage. He was later discharged home on folic acid and prophylactic antimalarials.

After the discharge, the patient continued on out-patient basis, to receive physiotherapy once a week for the first two months and thereafter, once a month throughout the six-year period of follow-up. For routine physical

evaluation, he attended the clinic once in every three months. Compliance to monthly physiotherapy and to the three - monthly clinic attendance was satisfactory. Physical evaluation during each clinic attendance included anthropometric measurement of weight and height which were plotted against the NCHS growth chart percentiles (Fig 3). It will be observed from the growth curve (Fig 3) that the weight for age was on, or below the 5th percentile, while the height was around the 25th percentile, during the six-year follow-up. At the age of 10 years in September 1996, his weight was 21kg, (below the 5th percentile) and the height was 133cm, (on the 25th per-

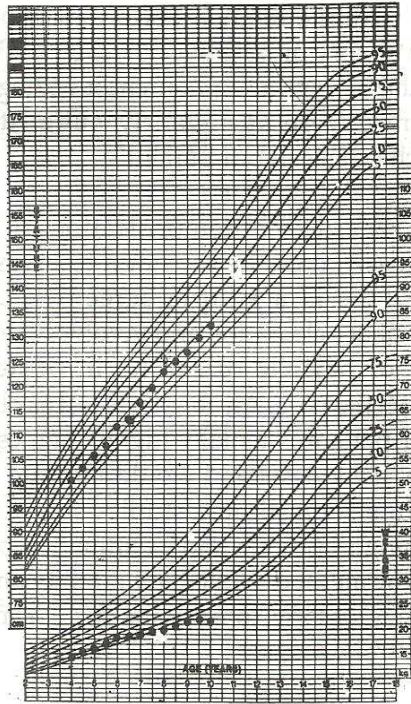


Fig 3 - Growth curves of the patient from age 4 to 10 years compared with the NCHS percentiles. Measurements of weight and stature were plotted at 6-monthly intervals. Note the poor weight gain (on or below 5th percentile) and the oscillation of height around the 25th percentile.

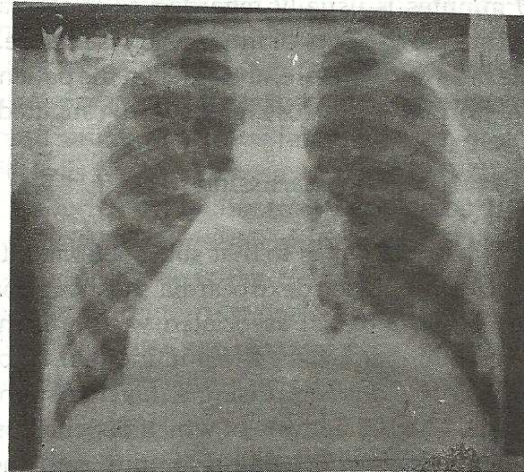


Fig 4 Chest radiograph (PA view) of the patient at the age of 10 years showing no obvious changes from the initial one.

centile). Thus, the patient was underweight although stunting had not yet manifested. There was only one recurrence of severe lower respiratory infection requiring a second admission during the six-year follow-up period. The second chest radiograph (Fig 4) taken in September 1996, showed no changes from those seen on the initial film.

The saccharin test (of mucociliary clearance) was recently carried out on the patient, his parents and two of his siblings according to the method described by Rees.⁹ The sweet taste of the saccharin was detected in the mouth of the patient 33 minutes after instillation of 0.5mm particle of pure saccharin (*Searle Laboratories, High Wycombe, England*) posteriorly through the nose. The corresponding times for the father, mother, and two siblings were 10.3, 9.8, 10.5 and 11.3 minutes respectively (mean: 10.4 minutes). In normal individuals, the sweet taste of the saccharin would be detected within 10 minutes; any time greater than 30 minutes is usually regarded as abnormal and suggestive of poor mucociliary clearance.⁹ The test was therefore, abnormal in the patient and normal in the close relatives investigated.

Discussion

Our patient belongs to that subset of patients with mirror-image dextrocardia (dextrocardia and situs inversus) associated with bronchiectasis and sinusitis - the multisystem association of lesions comprising Katagener's syndrome,¹⁻³ the diagnosis of which depends on the combination of clinical features and the demonstration of abnormalities in the ultrastructure and function of the cilia.⁹ The clinical evidence of the syndrome in our patient was not in doubt and was supported by ra-

diological, ultrasonographic and electrocardiographic findings confirming mirror image dextrocardia and radiological evidence of sinusitis and bronchiectasis. Until recently, the diagnosis of bronchiectasis was made by bronchography, an invasive procedure which has now been supplanted by a non-invasive computed tomography (CT) scan of the lungs which has indeed become the gold standard for the diagnosis of this condition. A CT scan was planned for our patient but could not be done due to financial constraint, while arrangements for bronchography were cancelled when the patient developed adverse reactions to the potassium iodide contained in an expectorant used to prepare him for the procedure. Despite the non-performance of these confirmatory procedures however, we believe that the history and plain chest radiographic findings were sufficiently suggestive of bronchiectasis in our patient.

With regard to a demonstration of ciliary dyskinesia, only the saccharin test was available. This is a simple screening test of mucociliary clearance, and involves the movement of particle of saccharin posteriorly through the nose. An abnormal test as obtained in our patient is usually highly suggestive of ciliary dyskinesia and would indicate a need for more sophisticated studies such as nasal brushing technique and examination by photometric method¹⁰ for ciliary motility and electron microscopy to examine for a variety of structural defects.^{6,9}

Complete mirror-image visceral arrangement is said to be associated with a high incidence of affected sibs and very high consanguinity. A simple autosomal recessive basis has been suggested for this, although the recurrence

risk is much less than one in four.¹¹ In the case of Kartagener's syndrome where mirror-imagery is associated with sinusitis and bronchiectasis due to abnormal cilia, there is one in four recurrence risk for anomalies of the cilia, but only one in eight recurrence risk for organ derangement.¹¹ Although our patient was a product of a consanguinous marriage, we could not find clinical or radiological evidence of mirror image dextrocardia in the parents or sibs. Similarly, there was no clinical evidence in the sibs to suggest primary ciliary dyskinesia while the saccharin test was negative in them. It has been observed that as the condition of immotile cilia syndrome, to which Kartagener's syndrome belongs, is present from birth, it can produce symptoms of respiratory distress as early as the neonatal period.^{12,13} History of respiratory distress in the neonatal period was not elicited in our patient. This is not unusual since the majority of patients present later with chronic upper and lower respiratory tract disease.⁶ Secretory otitis media and conductive hearing loss which are said to be relatively common in this syndrome,^{5,6} were not observed in our patient.

The term dextrocardia refers to a right sided cardiac mass, regardless of how it got into that position.^{14,15} Dextrocardia may be the result of embryologic error (as in Kartagener's syndrome) or it may be due to congenital or acquired shift of the mediastinal contents, as with agenesis of the lungs, lobar emphysema or pneumothorax.¹⁴ Van Praagh and Vlad¹⁴ have given an excellent account of how the understanding of every complicated malposition of embryologic origin is facilitated by systematically analyzing the heart in a segmental manner. Concordance of viscera and heart - leuocardia in situs solitus or dextrocardia in

situs inversus, is associated with a lower incidence of congenital heart disease than is seen when the heart and viscera are discordant.¹⁴ While the incidence of mirror-image dextrocardia is reported to be about 1:10,000 live births in the United States,¹⁵ its incidence in Nigeria is unknown, but it is believed that the distribution of various cardiac defects is similar to that found in cases of situs solitus and normal cardiac position.¹⁵ Our patient did not present with signs suggesting serious underlying cardiac lesion to warrant referral for invasive cardiological investigations.

There is sparse literature on the long term prognosis or natural history of Kartagener's syndrome and associated syndromes. As most of these abnormalities are structural, they are irreversible and therapy is usually directed at vigorous treatment of intercurrent infections with antibiotics and physiotherapy to delay the progression of bronchiectasis.⁶ Our patient has so far, been regularly followed up for six years and has done well on physiotherapy and antibiotics as evidenced by the apparent lack of progression of the bronchiectatic changes of the chest radiographs. It is known that in bronchiectasis from any cause, recurrent infections of the lower respiratory tract are common, tend to persist and are difficult to control. During acute exacerbations, there may be haemoptysis as indeed occurred on one occasion in our patient. Associated anorexia and subsequent poor weight gain are also common.⁶

The high socio-economic status of the parents of our patient made compliance to regular follow-up feasible. Miller and Divertie³ have described a 72-year old female with the classical Kartagener's syndrome, suggesting that with reasonable medical supervision, this syndrome

may be compatible with a full life span. Particular attention should be paid to the detection and treatment of conductive hearing loss in children with the syndrome. Furthermore, as males with Kartagener's syndrome are infertile because of reduced sperm motility, adult males will require appropriate testing and counselling for infertility.^{5,6}

Acknowledgements

We are grateful to Dr Jutta Quinkenstein, Chief Consultant Radiologist, Specialist Hospital, Sokoto, for the ultra-sonographic evaluation of the patient, to Dr Mehta, Chief Consultant ENT Surgeon for his role in the investigation and management of the patient and to Umar S Maikulki for secretarial assistance.

References

- 1 Kartagener M. Zur pathogenese der Bronchiktasien 1. Mitteilung: Bronchiektasien bei situs viscerum inversus. *Beitr Klin Enforsch Langenkr* 1993; 83: 489-501.
- 2 Logan WD, Abbott OA, Hatcher CR. Kartagener's triad. *Dis Chest* 1965; 48: 613-6.
- 3 Miller RD, Divertie MB. Kartagener's syndrome. *Chest* 1972; 62: 130-5.
- 4 Afzelius BA, Eliasson B, Johnsen O, Lindhomer C. Lack of dynein arms in immotile human spermatozoa. *J Cell Biol* 1975; 66: 225-30.
- 5 Afzelius BA. A human syndrome caused by immotile cilia. *Science* 1976; 193: 317-9.
- 6 Dinwiddie R. Immune disease and the lung. In: Dinwiddie R, ed. *The Diagnosis and Management of Paediatric Respiratory Diseases*. Edinburgh: Churchill Livingstone (Publishers) Ltd. 1990: 127-46.
- 7 Rott HD. Genetics of Kartagener's syndrome. *European J Resp Dis* 1983; 64 (Suppl 127): 1-4.
- 8 United States Department of Health, Education and Welfare. National Center for Health Statistics (NCHS) Growth charts. *Mon Vital Stat Rep* 1976; 25 (suppl 3): 76-120.
- 9 Rees J. Defects of mucociliary function. In: Rees J, ed. *Diagnostic Tests in Respiratory Medicine*. London: Chapman and Hall (Publishers) Ltd. 1988: 179-85.
- 10 Rutland J, Cole PJ. Non-invasive sampling of nasal cilia for measurement of beat frequency and study of ultrastructure. *Lancet* 1982; 2: 564-5.
- 11 Burn J. The aetiology of congenital heart disease. In: Anderson RH, Shinebourne EA, Macartney FJ, Tyrian M, eds. *Paediatric Cardiology*. Vol 1. Edinburgh: Churchill Livingstone (Publishers) Ltd. 1987: 15-63.
- 12 Ramet J, Byloos J, Delree M, Saepe L, Clement P. Neonatal diagnosis of the immotile cilia syndrome. *Chest* 1986; 90: 138-40.
- 13 Whitelaw A, Evans A, Corrin B. Immotile cilia syndrome: a rare cause of neonatal respiratory distress. *Arch Dis Child* 1981; 56: 432-5.
- 14 Van Praagh R, Vlad P. Dextrocardia, mesocardia and levocardia: the segmental approach to diagnosis in congenital heart disease. In: Keith JD, Rowe RD, Vlad P, eds. *Heart Diseases in Infancy and Childhood*. New York: Macmillan (Publishers) Ltd. 1978: 638-95.
- 15 Emmanouilides GC, Granvanis MB. Malposition of the heart. In: Granvanis MB, ed. *Cardiovascular Disorders: Pathogenesis and Pathophysiology*. St. Louis: Mosby (Publishers) Ltd. 1993: 436-44.