

# Prune Belly Syndrome in Sagamu: Report of Three Cases with Typical and Atypical Features

AF Adekanmbi,\* MB Fetuga,\* TA Ogunlesi,\* MM Ogundeyi,\*\* F Gbadebo,+ A Oyinlade+

## Summary

Adekanmbi AF, Fetuga MB, Ogunlesi TA, Ogundeyi MM, Gbadebo F, Oyinlade A. Prune Belly Syndrome in Sagamu: Report of Three Cases with Typical and Atypical Features. *Nigerian Journal of Paediatrics* 2006; 33: 22. Prune belly is a rare congenital anomaly that is commonly seen in males. We report two male cases and a phenotypic female with absent abdominal wall musculature that were seen within one year at the Olabisi Onabanjo University Teaching Hospital, Sagamu. These cases are reported to create a better awareness of this disorder in this environment. This, to our knowledge, is the first report of prune belly syndrome in our centre.

## Introduction

PRUNE belly syndrome (PBS) has many acronyms such as Eagle-Barret syndrome,<sup>1</sup> the triad syndrome and Obrinsky syndrome.<sup>2</sup> It was first described over a century ago by Frohlich, as the absence of abdominal musculature in a child. Twenty years later, Parker described other associations, and it was subsequently named "The Prune Belly Syndrome". The constant characteristics are hypoplasia of the abdominal wall, cryptorchidism and urinary tract anomalies. It has been postulated that these abnormalities arise either as a result of early urethral obstruction or more likely, due to a primary defect of the intermediate and lateral plate mesoderm which affects the embryogenesis not only of the mesonephric and paramesonephric ducts but also of the musculature of the abdominal wall and urinary organs.<sup>3</sup> In addition, there may be involvement of the cardiopulmonary, gastrointestinal and musculoskeletal systems.<sup>4,5</sup> The association of PBS with chromosomal anomalies such as Trisomy 18 and Beckwith-Wiedemann syndrome have also been reported.<sup>6,7</sup>

The incidence of PBS is reported to be 1 in 30,000 - 50,000 births. Although associated with young

maternal age, the precise aetiology is uncertain. However, sex influenced autosomal mode of inheritance has been suggested.<sup>8,9</sup> While there have been reports of this syndrome from Ibadan,<sup>4</sup> the exact incidence in Nigeria is unknown. It is probably rare but it is also likely that some cases are missed in clinical practice due to poor awareness and constraints in investigation. In view of this, we are reporting three cases of prune belly syndrome seen in Sagamu, within a period of one year.

## Case Reports

### Case 1

OA, a two-month-old male infant presented with absence of both testes noticed since birth; this was associated with wrinkling of the abdominal wall and progressive abdominal distension. His urinary output was apparently normal. The mother was a 22-year old para2+0 who did not receive antenatal care but took several herbal preparations of unknown constituents throughout pregnancy. He was delivered at term, in a church. The sibling did not have similar features. Physical examination revealed an apparently well infant who weighed 6.5 kg and had no facial dysmorphic features. The abdomen was pendulous and wrinkled with visible dilated bowel loops. The hypoplastic scrotum was empty and the phallus was normal in size. The testicles were not palpable. There were no other congenital malformations (Fig. 1).

Abdominal ultrasound showed normal sized kidneys with hydronephrosis. Intravenous urography (IVU) was not done for financial reasons and the child defaulted from further follow-up.

---

Olabisi Onabanjo University Teaching Hospital,  
Sagamu

Department of Paediatrics

\* Consultant/Lecturer

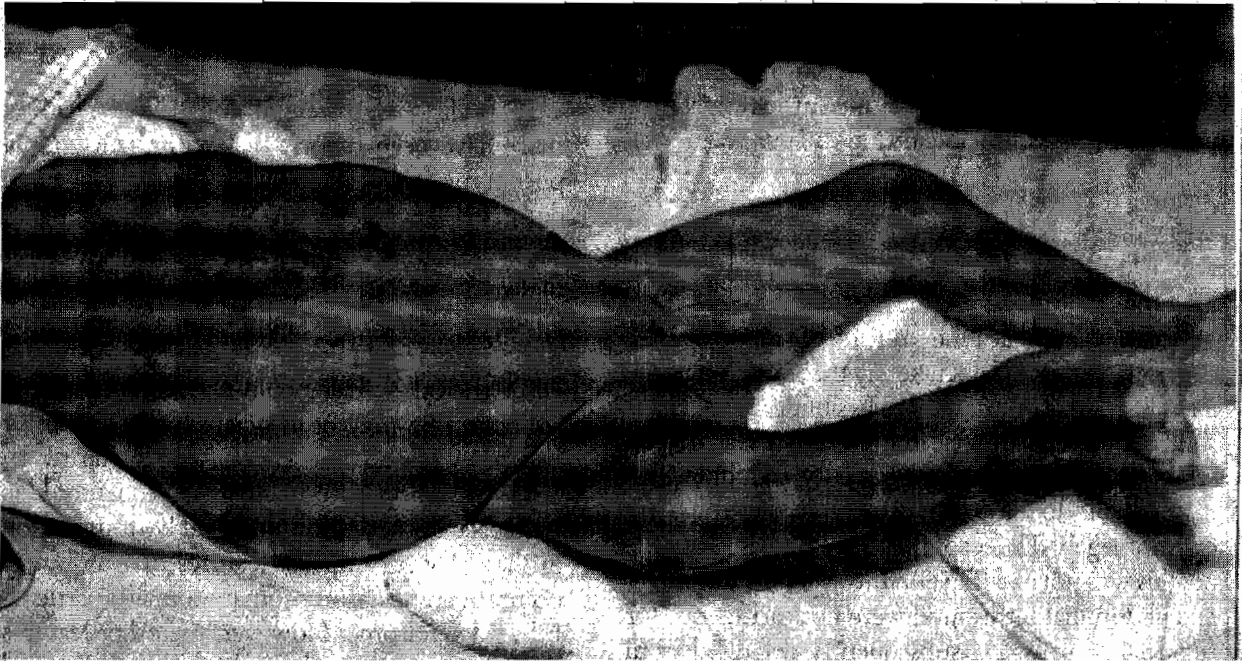\*\* Senior Registrar

+ Registrar

---

Correspondence: Dr AF Adekanmbi.

Email: [wonlash@yahoo.com](mailto:wonlash@yahoo.com)



*Fig. 1: Photograph of Case 1, showing pendulous and wrinkled abdomen with visible and dilated loops of bowel*

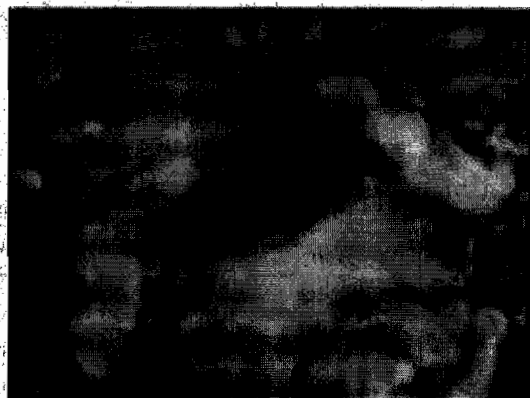#### *Case 2*

OB, an 11-hour-old female baby, was referred on account of low Apgar scores and multiple congenital anomalies. She was a product of term pregnancy delivered at a health centre by spontaneous vertex delivery (SVD). The mother was a 17-year old primipara who had febrile illnesses in the first and second trimesters for which she took herbal preparations of unknown components. She also had oligohydramnios.

The baby weighed 2.4kg and had bilateral microphthalmia, low set ears, bilateral clinodactyly, rocker bottom feet and positive ortholani test for hip dislocation. Her occipito-frontal circumference was 36 cm with wide anterior fontanelle measuring 8cm

by 9cm. There was global hypertonia but the spine was grossly normal. She also had pectus excavatum with a prominent xiphisternum. The abdomen was flat and wrinkled with a central defect covered with a membrane but the external genitalia were grossly normal. Perinatal asphyxia with omphalocele, a syndrome of absent anterior abdominal wall musculature and possible Edward syndrome constituted the initial assessment. Prune belly syndrome with possible Edward syndrome was diagnosed after further evaluation (Fig. 2).

She was adequately resuscitated but certain investigations such as chest X-ray, intravenous urography, and chromosomal analysis by karyotyping



*Fig. 2: Photograph of Case 2 showing pectus excavatum and a central abdominal wall defect covered with a membrane*

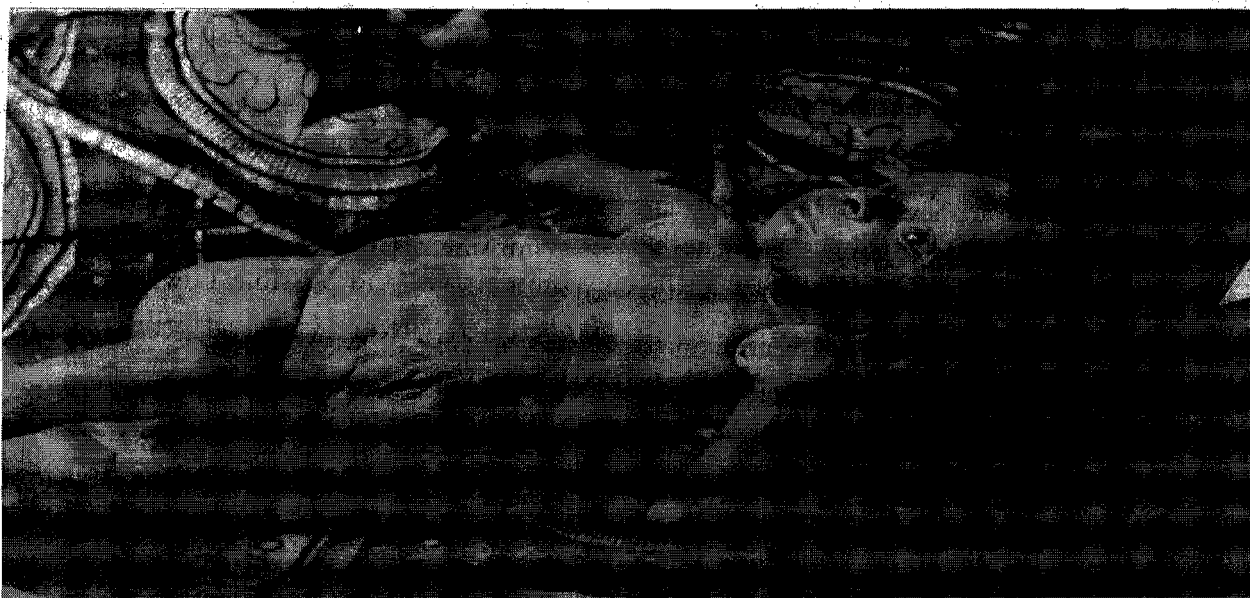
were not done for logistic reasons. The patient developed apnea on the second day of life and subsequently lapsed into unconsciousness. She died on the third day of admission; autopsy was not performed due to socio-cultural disapproval.

### Case 3

AE, a 44-day-old boy presented with empty scrotal sacs and flabby abdomen. The 35-year-old para 5 mother had a febrile illness during the first trimester of pregnancy but did not take any traditional medicine including herbal preparations. His siblings did not have similar disorders. Physical examination revealed a boy with flabby abdomen and easily palpable and displaceable loops of intestine but there was no organomegaly. The scrotum was hypoplastic but the phallus was normal (Fig. 3). Intravenous urography and abdominal ultrasound were not carried out for financial reasons. He subsequently defaulted from further follow up.

anomalies and uterine duplication which are known to occur in the female equivalent of PBS,<sup>10</sup> could not be evaluated in this phenotypic female patient, there were no clinical features indicative of such. Although there have been reports of PBS in genotypic and phenotypic females,<sup>10</sup> cases of PBS may still be missed due to poor awareness or constraints in investigation. This may explain the seeming rarity of this disorder in this environment.

One of the males had hydronephrosis, a complication of the urinary tract anomaly seen in PBS, while the other male could not be investigated. In addition, PBS may be associated with Trisomies 18 and 21,<sup>6</sup> while anomalies involving the heart, trunk and lower limbs do occur albeit, infrequently. Hence, both pectus excavatum and rocker bottom feet found in Case 2 were unusual features of PBS but may occur in certain chromosomal anomalies particularly Edward syndrome. However, the other features in this patient were not classical of either an Edward or Down syndrome. The presence of hip dislocation and other limb deformity in the second case lends



*Fig. 3: Photograph of Case 3 showing flabby abdominal wall*

### Discussion

PBS is regarded as essentially a male disease, nevertheless a modified form of the syndrome has been reported in females.<sup>8-10</sup> Two of the cases presented (Cases 1 and 3) were males conforming to the known sex predilection in PBS. Case 2, which was a phenotypic female, was an unusual case. The phenotypic sex may be an aberration but we could not confirm the genotypic sex of the baby. Therefore, Case 2 may well be a syndrome of absent abdominal wall musculature or a modified female phenotypic form of PBS. Although the presence of urinary tract

credence to earlier reports that orthopaedic problems may occur in females with PBS.

Is the modification of PBS in the female genetic? Indeed, there are theories about the aetiology of this disease,<sup>8-10</sup> although we could not verify the possible role of genetics by chromosomal analysis in our patients. Nevertheless, the use of herbal preparations in early pregnancy in two of the cases may support earlier suggestion of disturbed embryogenesis as the basis of the disorder.<sup>8,11</sup> The relatively young maternal age in two of our cases was also in keeping with other reports,<sup>6</sup> while the third patient with advanced

part of the country in which the mother was 38 years old.<sup>12</sup>

The prognosis in PBS though hitherto reportedly poor, has since improved with prenatal diagnosis.<sup>2</sup> Unfortunately, only very few centres in the country offer prenatal diagnostic services and most expectant mothers do not avail themselves of formal antenatal care. None of the mothers in this report had formal antenatal care. If they had received antenatal care and prenatal diagnosis, the affected families would probably have been more prepared for the care of the babies. The natural grief reaction accompanying the birth of dysmorphic babies in families that are not prepared for such has been reported.<sup>12</sup> Early neonatal death does occur in PBS; this is dependent on the degree of pulmonary hypoplasia and renal dysplasia.<sup>13</sup> Although none of these possible associated disorders was confirmed in our patients, it is plausible that they could be contributory.

Our inability to adequately investigate these babies for reasons of poor finances was a major problem in the management of these patients and might have been responsible for their eventual loss to follow up. There is, therefore, a need to make health care free for children, particularly those with illnesses and disorders that make them prone to neglect and default. This may encourage and improve health seeking behaviour in the parents and improve the long term prognosis of these patients. Support groups need to be formed in order to provide necessary information and psychological support for affected families. Similarly, physicians practising in this environment need to be aware of this disorder and its various modifications for improved case management.

## References

1. National organization for rare disorders. Prune Belly Syndrome Network. [www.raredisease.org/search/rdbd](http://www.raredisease.org/search/rdbd). Last updated: September 11, 2006. Date accessed: September 15, 2006.
2. Franco I. Prune belly syndrome. [www.emedicine.com/med/topic3005.htm](http://www.emedicine.com/med/topic3005.htm).
3. Stephens FD, Gupta D. Pathogenesis of the prune belly syndrome. *J Urol* 1994;152:2328-31.
4. Adeyokunnu AA, Adeniyi A, Kolawole TM, Nkposong EO. Prune belly syndrome. A study of ten cases in Nigerian children with common and uncommon manifestations. *East Afr Med J* 1975;52:438-9.
5. Jennings RW. Prune belly syndrome. *Semin Pediatr Surg* 2000;9:115-20.
6. Nivelon-Chevallier A, Feldman JP, Justrabo E, Turc-Carel C. Trisomy 18 and prune belly syndrome. *J Genet Hum* 1985;33:469-74.
7. Watanabe H, Yamanaka T. A possible relationship between Beckwith-Wiedemann syndrome, urinary tract anomaly and prune belly syndrome. *Clin Genet* 1990;38:410-4.
8. Stephens FD, Gupta D. Pathogenesis of the prune belly syndrome. *J Urol* 1994;152:2328-31.
9. Ramasamy R, Haviland M, Woodard JR, Barone JG. Patterns of inheritance in familial prune belly syndrome. *Urology* 2005;65:1227.
10. Reinberg Y, Shapiro E, Manivel JC, Manley CB, Pettinato G, Gonzalez R. Prune belly syndrome in females: a triad of abdominal musculature deficiency and anomalies of the urinary and genital systems. *J Pediatr* 1991;118:395-8.
11. Walker J, Prokurat AI, Irving IM. Prune belly syndrome associated with exomphalos and anorectal agenesis. *J Pediatr Surg* 1987;22:215-7.
12. Okeniyi JAO, Ogunlesi TA, Dedek IOF, Oyelami OA, Oyedeji GA. Prune belly syndrome in a Nigerian child. *Internet J Pediatr Neonatol* 2005;5:2.
13. Gonzalez R. Obstructions of the urinary tracts. In: Behrman RE, Kleigman RM, Arvin AM, eds. *Nelson Textbook of Pediatrics*. Philadelphia: WB Saunders, 1996: 1534-42.

Last updated: March 8 2006. Accessed on September 14, 2006.