

**Oloyede IP
Ekpe E
Okorie OO**

Bronchial foreign body misdiagnosed as pulmonary tuberculosis

DOI:<http://dx.doi.org/10.4314/njp.v40i4.19>

Accepted: 20th February 2013

Oloyede IP (✉)
Okorie OO
Department of Paediatrics,
University of Uyo Teaching Hospital,
PMB 1136, Uyo, Akwa Ibom State,
Nigeria
E-mail: isooloyede@yahoo.com
Tel +2348068889226

Ekpe E
Cardiothoracic unit,
Department of Surgery,
University of Uyo Teaching Hospital
PMB 1136, Uyo, Akwa Ibom State,
Nigeria

Abstract Retained and neglected foreign bodies in the respiratory tract in children are a common occurrence. Undiagnosed foreign bodies can cause mechanical effects or chemical reactions and may present as chronic pulmonary infection, bronchiectasis, asthma, and lung collapse or lung abscess. Delay in diagnosis, appears to result from a failure to give serious consideration to the diagnosis, normal chest roentgenographic findings, and negative bronchoscopic findings. A

case of left bronchial foreign body aspiration is herein reported to illustrate the causes and complications of the delayed diagnosis. It is hoped that this will help sensitize the medical practitioner of the need for a high index of suspicion in children presenting with symptoms suggestive of foreign body aspiration. This study will also serve as advocacy for the provision of adequate bronchoscopic equipments for paediatric practice in our health facilities.

Case report

An 11 year old male presented with a four years history of recurrent wheezing and cough and a two years history of difficulty in breathing, recurrent fever and weight loss. The child had earlier presented to the Ear, Nose and Throat Department of the University of Uyo Teaching Hospital four years earlier with the complaints of wheezing which the mother noticed after he inhaled a balloon component, while blowing a whistle with a balloon attached to it. There was associated discomfort in the throat when he tried to cough. He was not a known asthmatic and he had completed his immunizations according to the National Programme for Immunization (NPI) schedule.

He was the last of five children two males and three females, elder siblings are alive and well. Mother is a 39year old civil servant with secondary level of education, while father had died of an unknown illness. There was no contact with an adult with chronic cough.

Examination findings revealed a respiratory rate of 20breaths/minute, vesicular breath sounds with transmitted sounds and localized rhonchi on the left hemithorax. He was admitted in the paediatric ward after a diagnosis of foreign body in the left bronchus was made. An urgent chest radiograph done was normal, his haemoglobin concentration was 10g/dl and his Human Immunodeficiency Virus (HIV) serology screening was negative. He had an urgent rigid bronchoscopy which was unsuccessful because of inappropriate equipments.

Two days into admission he developed high grade fever with laboured breathing. Chest examination findings,

included dyspnoea, vesicular breath sounds with bilateral crepitations and rhonchi. He was placed on intravenous (IV) Ceftriazone 1g daily for five days, intramuscular (IM) arthemether 60mg b.d for six days and IV hydrocortisone 100mg dly for three days. Clinical features of lower respiratory tract infection later resolved and he was discharged on the seventh day of admission on oral cefuroxime 250mg b.d for five days and told to come for a repeat bronchoscopy a week later. The repeat rigid bronchoscopy was done two weeks after the first one and no foreign body was visualized. He was thereafter discharged home on caps Ampiclox 500mg 6hrly after an initial 24 hours of Ampiclox through the intravenous route.

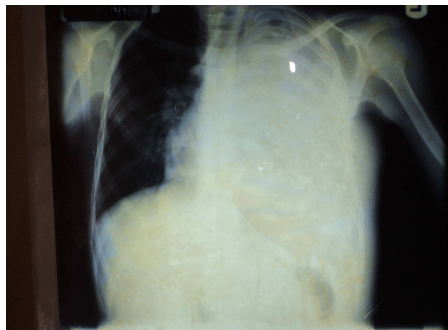
With persistence of symptoms he presented at the University of Calabar Teaching hospital where another bronchoscopy was done and no foreign body was visualized. During the period he had two episodes of haemoptysis and was seen in a health centre and placed on six months of anti-tuberculous medications, after sputum Acid and Alcohol Fast Bacilli (AAFB) was tested for, though mother was not aware of the test results, but symptoms persisted and hereafter the mother resorted to herbal medications and prayers in the church.

Two years later the patient represented to the children emergency unit of UUTH, with complaints of cough and difficulty in breathing of two months duration, with fever and weight loss of one month duration. The cough was insidious in onset and initially productive of frothy sputum, which later became purulent, there was no haemoptysis and no history of contact with persons with

chronic cough. Difficulty in breathing was progressive, initially on exertion but later occurred also at rest, it was worsened by bouts of cough. Chest pain was present especially over the left hemi thorax, stabbing, worse on coughing or movement and relieved by rest. There was associated orthopnoea and paroxysmal nocturnal dyspnoea. Fever began a month later, insidious in onset, high grade and intermittent and transiently relieved by tablet paracetamol. Weight loss was progressive with a poor appetite. For the above he was taken to general hospital Abak where purulent fluid was aspirated from the left side of the chest using a syringe and needle and he was referred to UUTH for expert management.

Physical examination revealed an acute on chronic ill looking child, febrile with a temperature of 38.7°C, wasted with prominent ribs and scapulae, moderately pale, dyspneic and tachypneic, acyanosed, grade 2 finger clubbing, nil peripheral lymphadenopathy and nil pedal edema. The body weight was 26kg (81% of expected). Respiratory system examination revealed a tachypneic (RR=48cy/min) and dyspneic child with intercostal and subcostal recession. The trachea was central with a bulging and tender left anterior chest wall. There was reduced chest expansion, reduced tactile fremitus and stony dull percussion notes over the left hemithorax. Breath sounds were bronchial in the upper left lung zone. Air entry in the left hemithorax was decreased in the mid and absent in left lower zone. There was no evidence of cardiomegaly or cardiac failure and examination of other systems was essentially normal. A diagnosis of bronchiectasis with left lung collapse and left empyema thoracis to R/O Left Tuberculous empyema and left lung collapse was made. An urgent close tube thoracotomy drainage, (CTTD) under local anaesthesia was productive of thick purulent fluid which later on became seropurulent, because of the viscosity of the fluid the CTTD was not very effective. A review chest x-ray showed interval improvement with appearance of lung substance close to the left lateral chest wall with mediastinal shift to the left and left lung collapse.(Fig 1) He was thereafter commenced on IV Ceftriazone 1g 12hrly and Gentamicin 40mg 8hrly.

Fig 1



The patient was reviewed by the cardiothoracic unit and plans were made to do an open thoracotomy with decortication. A post intubation chest radiograph later showed a central trachea with an area of homogenous consolidation in the left upper lobe with surrounding areas of patchy consolidation and left lung collapse. The

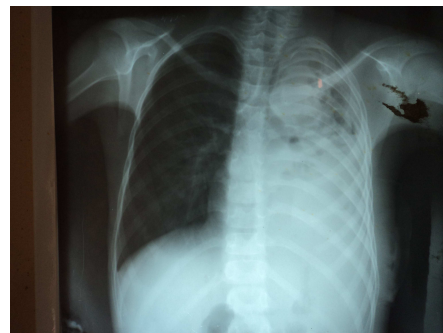
Packed Cell Count (PCV) was 29%, Mantoux test was 10mm, a tuberculous score was 10/15 and child was referred to the DOTS unit where he was recommenced on anti-tuberculous medication for six months as a case of treatment failure but mother declined the drugs. He was discharged after spending four weeks on admission

Four years after the first presentation child was seen with similar complaints of cough, difficulty in breathing, chest pain and inability to lie flat. The general physical examination showed a chronically ill looking child, in respiratory distress, afebrile (36°C), grade III finger clubbing, no peripheral lymphadenopathy, with a weight of 26kg(80% of expected). The child was tachypneic and dyspneic with a respiratory rate of 48cy/min. The trachea was deviated to the right, with reduced chest expansion and tactile fremitus on the left mid/lower lung zones. The percussion notes were stony dull in the left mid/lower lung zones while they were resonant on the right.

Air entry was reduced in the left upper lung zone and absent in the mid/lower zones while there was good air entry on the right. Breath sounds were bronchial on the left upper lung zone, absent in the left mid/lower lung zones and vesicular on the right hemithorax. There were no crepitations.

Diagnostic thoracentesis yielded free flowing offensive rice water like aspirate with the impression of thickened parietal pleura. Other systems were essentially normal. A diagnosis of bronchiectasis with left lung collapse and empyema thoracis was made. A pre-intubation x-ray showed homogenous opacity of the left hemithorax with minimal apical sparing with obliteration of the costophrenic and cardiophrenic angles and air-fluid levels, mediastinal shift to the right with apical cavitary lesions on the left lung and right hilar opacities. (Fig 2)An urgent PCV was 24% while a repeat mantoux test had no wheal. The sputum AAFB was negative while sputum culture and sensitivity grew Klebsiella species which was sensitive to ofloxacin and levofloxacin. The HIV serology was negative.

Fig 2



An urgent CTTD was done with drainage of over 2000mls of offensive purulent fluid. The child was initially placed on IV Ceftriazone and Gentamicin but on getting the sensitivity result the drugs were changed to Tab Ofloxacin 100mg b.d for three weeks and child was commenced on chest physiotherapy, and reviewed by the public health physicians who also made a diagnosis

of bronchiectasis with recurrent empyema thoracis²⁰ to foreign body aspiration to R/O pulmonary tuberculosis. A Computerized Tomography scan showed a radio-opaque foreign body in the left main bronchus with a resultant collapse/consolidation of the left lung and dilated left bronchioles (Fig 3). The plan was to attempt bronchoscopic removal of the foreign body with possible progression to thoracotomy and bronchotomy if bronchoscopic removal failed, but due to lack of the appropriate bronchoscope, the child was referred to the cardiothoracic unit of university of Nigeria teaching hospital Enugu for surgery.

The final diagnosis was Collapse/ consolidation of the left lung and chronic empyema thoracis²⁰ to foreign body in the left main bronchus

Child was seen in the CTSU clinic three months after the surgery, he was still having cough productive of purulent sputum but with no fever and was now able to tolerate exercise (football).

Examination findings showed a weight of 30kg (increased), trachea was deviated to the left, decreased chest expansion on the left, increased tactile fremitus and vocal resonance on the left hemithorax, dull percussion notes with bronchial breath sound on the left upper zone and absent breath sounds on the left mid/lower zone. A diagnosis of persistent atelectatic left lower lobe was made. He was commenced on tab tinidazole 250mg bd for two weeks, tab cefuroxime 250mg b.d and syrup broncholyte 10ml t.d.s for 10 days.

He defaulted from follow up and was seen five months later in the children outpatient department, when he still had complaints of productive cough and the examination findings were basically the same as what was seen in the previous visit to the CTSU unit

Discussion

Inhalation of foreign bodies is a very serious condition in childhood and may result in an acute respiratory distress, chronic and irreversible lung damage or even death. Early diagnosis and removal of foreign bodies must be achieved to avoid complications.¹ Forty two to 55% of patients with foreign bodies in the airways are between one and three years of age.^{1,2,3} The location of a foreign body is dependent not only on its size and shape but also on the position taken by child at the time the aspiration takes place.^{4,5} In 5-60% it is located in the left bronchus while in 30-40% it is seen in the right bronchus and in the trachea in 10-15%.^{4,5} The most common presentations of bronchial foreign body aspiration include recurrent cough, wheezing, dyspnoea and decreased breath sound especially asymmetrical auscultation.^{1,6} These were all present in the index case. Early diagnosis of foreign body in the airway has been hinged on the tripod of a history of foreign body inhalation, clinical presentation and radiographic findings.² This however has some shortcomings as an acute episode of inhalation may escape the notice of the caregivers, the child may not present with the classic symptoms and

because of the fact that most foreign bodies are radiolucent, the chest radiographs are frequently normal as was seen in the case presented.^{6,7}

Late diagnosis of foreign body has been defined as occurring beyond three days between aspiration of the foreign body, or onset of symptoms and the correct diagnosis.⁸ Some causes of late diagnosis that have been identified include, parental negligence,⁸ misdiagnosis by fellow professionals and paediatricians,⁹ normal chest roentgenographic findings,^{7,10} lack of typical symptoms and signs, mismanagement, negative bronchoscopic findings and lack of appropriate facilities for diagnosis.^{11,12,13} In the index case misdiagnosis by fellow professionals, a normal initial chest radiograph, negative bronchoscopic findings due to inappropriate equipment and mismanagement were the identified causes of the delayed diagnosis. It is well known that antibiotics and steroids can temporarily subdue a patient's reaction to foreign body aspiration as was in the index case.^{8,9} Thus the disappearance of cough, wheezing or the clearing of a pneumonia may reinforce a faulty diagnosis. On the other hand, reappearance of symptoms after treatment should alert one to the possibility of a foreign body aspiration.

Bronchoscopy has been shown to be an important tool in both the diagnosis and treatment of foreign body aspiration.^{1,3,7} The indication for bronchoscopy include foreign body aspiration, or suspicion of aspiration of foreign body as well as concomitant symptoms such as cough, difficulty in breathing and rise in temperature.^{14,15} The success of bronchoscopy is dependent on the appropriateness of the equipment and the expertise of the professional. In a case of an initial negative bronchoscopy, a second bronchoscopy should be considered even more carefully because it is more difficult and dangerous due to the mucosal damage and formation of granulation tissue caused by the initial bronchoscopy.⁷ Hence a search for the foreign body should be made just below the granulation tissue in a repeat bronchoscopy.⁸ This may have been the reason for failure to visualize the bronchial foreign body in the subsequent bronchoscopies in the index case.

Radiology is the primary means of confirming the diagnosis.⁶ However, it has been seen that most foreign bodies are radiolucent and so the chest radiographs are frequently normal.^{6,7} As a result computerized tomographic (CT) scan is increasingly being recognised as a more superior diagnostic tool. CT scan not only shows both opaque and non-opaque foreign bodies in the bronchial tree in many cases but also detects subtle air trapping not yet present in chest radiograph.⁷ In the index case an earlier resort to CT scan would have prevented the long term morbidity from the complications of foreign body aspiration and the unnecessary cost incurred by the caregivers in the treatment of recurrent pneumonia. The drawback in the use of CT scan however, is its radiation hazard and increased cost especially in resource poor setting.⁶ As presented in the index case it took the caregiver almost nine months to gather the resources for the

CT scan before a definitive diagnosis was made. Hence, although CT scan is a very sensitive test, it is usually reserved for the diagnosis of elusive cases of a foreign body aspiration.⁷

Retained and neglected foreign bodies in the respiratory tract are fraught with a myriad of complications. Common complications of undiagnosed foreign bodies include obstructive emphysema, recurrent pneumonia, lung abscess, cystic bronchiectasis, atelectasis of a lobe, asthma, lung collapse, bronchial stenosis^{2,7,8} and pneumomediastinum.³ The index case presented with most of the outlined complications. As a result of these complications most cases of retained foreign bodies are usually misdiagnosed. This was evident in the index case, which was misdiagnosed as a case of pulmonary tuberculosis, treated with anti-tuberculous medications for six months and would have had a second course but for the refusal by the caregivers. Li *et al* in his study gave the frequent misdiagnosis of foreign body aspiration to include pneumonia, bronchitis, pulmonary tuberculosis, laryngitis, and common cold.⁹

Conclusion

Aspiration of foreign body should be suspected in all cases of bronchopulmonary infection with an atypical course. Early diagnosis and removal may save the patient chronic illness, an existence as an invalid or possibly death. Despite the great progress in the methods of endoscopy and anaesthesia great difficulties and complications are still present owing to the limitation of diagnostic procedures.

We therefore recommend that the basic tools needed for the diagnosis and removal of foreign bodies including appropriate sized bronchoscopes and CT scan should be made available in all tertiary health centres. Training of professionals including otolaryngologist, pulmonologist and cardiothoracic surgeons should be emphasised as the diagnosis and treatment of foreign body in the airway requires a multi-disciplinary approach.

Conflict of interest: None

Funding: None

References

1. Ayed AK, Jafar AM, Owayed A. Foreign body aspiration in children: diagnosis and treatment. *Paediatr Surg Int* 2003;19(6):485-488
2. Abdulmajid OA, Ebied AM, Motaweh MM, Kleibo IS. Aspirated foreign bodies in the tracheobronchial tree: report of 250 cases. *Thorax* 1976;31:635-640
3. Korlaclu W, Korecka K, Dzielicki J. Foreign body aspiration in children diagnostic and therapeutic role of bronchoscopy. *Pediatr Surg Int* 2011;27:833-837
4. Zhijun C, Frigaro Z, Niankai Z, Jingjing C. Therapeutic experience from 1,428 patients with paediatric tracheobronchial foreign body. *J Pediatr Surg* 2008;43(4):7180-721
5. Tahir N, Ramsden WH, Stringer MD. Tracheobronchial anatomy and the distribution of inhaled foreign bodies in children. *Eur J Pediatr* 2009;168(3):289-295
6. Shurakumar AM, Naik AS, Prashanth KB, Shelly KD, Praveen DS. Tracheobronchial foreign bodies. *Indian J Pediatr* 2003;70(10):793-797.
7. Shin S, Kim W, Cheon J et al. CT in children with suspected Residual Foreign Body in airway after bronchoscopy. *Am J Roentgenol* 2009;192:1744-1751.
8. Lianca MU, Ping HC, Deqiang SM. The causes and complications of late diagnosis of foreign body aspiration in children: Report of 210 cases. *Arch Otolaryngol Head Neck Surg.* 1991;.117 :876-878.
9. Li CF, Sun YG, Chung WB, Huang ML, Wang GL. The causes of misdiagnosis of foreign body aspiration with an analysis of 64 cases. *Benjing Med J* 1983;5:91-93.
10. Cantanco AJ, Cataneo DC, Raiz RJ (Jr). Management of tracheobronchial foreign body in children. *Pediatr Surg Int* 2008;24(2):151-156
11. Anyanwu CH. Foreign body airway obstruction in Nigerian children. *J Trop Pediatr* 1985;31(3):170-173
12. Omotai LO, Ibekwe MU, George IO. Impacted foreign bodies in the larynx of Nigerian children. *J Med Med Sci* 2012; 3:217-221
13. Adoga AA, Kokong DD, Ma'an ND. Endobronchial metallic foreign body in a Nigerian child: management difficulties and the need for caution. A case report. *Cases J* 2009;2:7766
14. Jiagian SS, Jongwu S, Yanming H et al. Rigid bronchoscopy for inhaled pen caps in children. *J Pediatr Surg* 2009;44(9):1708-1711.
15. Arital CS, Godfrey S, Gross m, Keron E, Springer C. Suspected foreign body inhalation in children: what are the indications for bronchoscopy. *J Pediatr* 2009;155(2):276-280.