

Sani UM
Ahmed H

Kawasaki disease: an unusual presentation in a 14-year old boy in Sokoto, north western Nigeria

DOI:<http://dx.doi.org/10.4314/njp.v40i4.15>

Accepted: 31st March 2013

Sani UM (✉)

Ahmed H

Department of Paediatrics,
Usmanu Danfodiyo University
Teaching Hospital (UDUTH)
Sokoto-Nigeria.

Email: usmansani2005@yahoo.com

Abstract Kawasaki disease (KD) is an acute systemic vasculitis that mostly affects children less than 5 years. Occasionally, it may present with renal involvement of varying severity. In Nigeria and most of Africa, only a few cases of KD have been reported and these were among children within the typical age group.

We report an unusual case of Kawasaki disease with renal manifestation in a 14 year old adolescent. Apart from the principal features of KD comprising of high grade fever, non purulent conjunctivitis, polymorphous rash, right sided cervical lymphadenitis and symmetrical desquamative lesions of the digits of the hands and feet; our patient also had renal involvement. The renal manifestations included mild periorbital edema, oliguria, hypertension (140/90mmHg), hematuria(++), proteinuria(++), and elevated serum urea and creatinine

(8.3mmol/L and 1.9mg/dl respectively). He was managed with high dose aspirin at 80mg/kg/day. The dose was reduced (5mg/Kg/day) and subsequently stopped after serial echocardiography showed normal coronary arteries. Intravenous immune globuline (IVIG) could not be started due to non availability. Nevertheless, clinical signs resolved, renal function normalised after 6 weeks and echocardiographic picture did not deteriorate. Patient is currently on follow up at the paediatric cardiology clinic of UDUTH, Sokoto, Nigeria..

Conclusion: Kawasaki disease can occur even in older children and renal manifestation may be self limiting. This report highlights the need for high index of suspicion in all cases.

Key words: Kawasaki disease, renal involvement, Adolescent, Sokoto, North-western Nigeria.

Introduction

Kawasaki disease (KD) is an acute febrile illness characterised by widespread systemic vasculitis.^{1,2} It occurs primarily in young children under the age of 5 yrs^{3,4}. The disease has a worldwide distribution, but is most prevalent in Asia and other developed nations^{2,3}. Though considered less common in our environment³, the burden may actually be underestimated due to low index of suspicion.

As there is no specific laboratory parameter for confirmatory diagnosis of KD, diagnosis is made using clinical criteria which was first described by Tomasaku Kawasaki and adopted by the American Heart Association². Principal features required for diagnosis are presence of fever for at least 5 days together with four of five of the following signs: non exudative bilateral conjunc-

tival injection, polymorphous exanthem, cervical lymphadenopathy (>1.5cm), changes in extremities and oral changes^{2,4}. The acute vasculitic process in KD can also lead to disturbed haematological profile and abnormalities of the cardiovascular, renal and respiratory systems¹. Coronary artery lesions such as aneurysms and thrombosis occur in up to 25% of patients and are the most important cause of morbidity and mortality^{1,4}. Renal involvement is rare, but has been reported⁵⁻⁷. It can manifest with proteinuria, hematuria or even frank renal failure^{1,5-7}.

There are only few reports of KD in Africa including Nigeria and almost all were among children within the typical age group^{8,9}. Occurrence in adult and older paediatric age group is rare^{10,11}. We report an unusual case of Kawasaki disease in a 14 year old boy who presents with renal involvement

Case

A 14 year old boy presented with 2 weeks history of fever, skin rashes and redness of the eyes. There was no history of contact with children having skin rashes and his immunisation status was complete. He was initially treated with oral antibiotic, Paracetamol and antimalarial at home. Chlorpheniramine (Piriton) tablets were also given on suspicion of an allergic disorder. Two weeks after the onset of symptoms, he noticed peeling of his hands and feet which necessitated presentation to our hospital. On examination, he was afebrile, but had discrete right sided cervical lymph adenopathy (with the largest measuring 4x3cm) and symmetric desquamation of both hands and feet (See Fig. 1 and 2). He had mild peri-orbital puffiness, with slightly elevated blood pressure (140/90mmHg or >95th percentile for age). A diagnosis of Kawasaki disease was considered based on clinical criteria². Complete blood count showed WBC of $11.8 \times 10^3/\mu\text{L}$ with relative neutrophilia ($8.2 \times 10^3/\mu\text{L}$) and platelet count of $277. \times 10^3/\mu\text{L}$. Erythrocyte sedimentation rate (ESR) was 20mm/hour. Urinalysis showed hematuria (++) and proteinuria (++) . Serum Urea and Creatinine were slightly elevated (8.3mmol/L and 1.9mg/dl respectively). Echocardiography showed normal Coronary arteries (Fig 3). Blood and urine cultures were negative. In view of strong suspicion of Kawasaki disease with renal manifestation, patient was commenced on high dose Aspirin at 80mg/Kg/day. Intravenous immune globulin (IVIG) could not be started due to non availability.

Fig 1: Cervical lymphadenitis. Note the arrows showing enlarged cervical lymph nodes in the patient

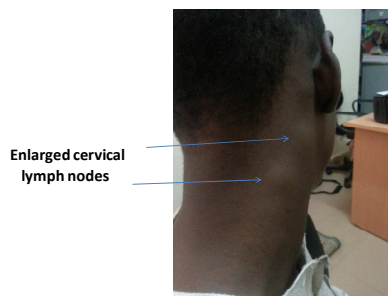


Fig 2: Symmetric desquamation of the hands in the patient with Kawasaki Disease

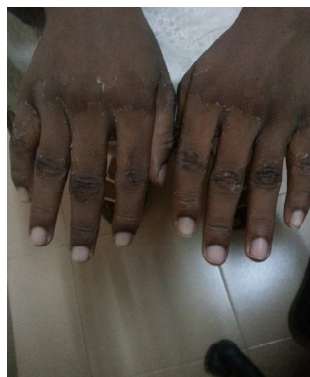

Fig 3a: A Parasternal short axis view (PSAX) showing normal right coronary artery (RCA) in the patient at presentation. Note the labelled arrow pointing at the RCA.

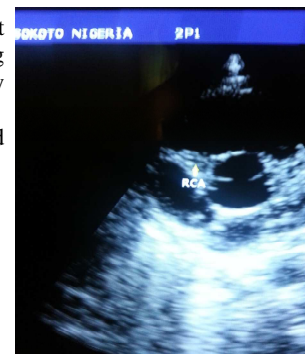
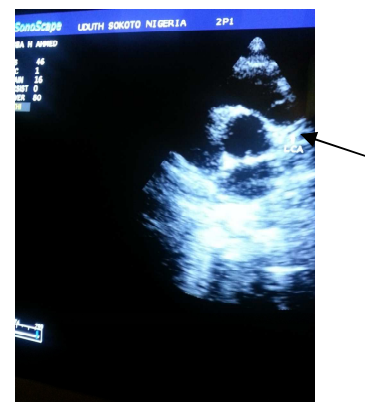

Fig 3b: Parasternal short axis view at aortic level showing normal Left coronary artery (indicated by an arrow)



There was clinical improvement with significant regression of lymph adenopathy, resolution of oedema and normalisation of renal function. However, his blood pressure remained slightly elevated (140/85mmHg) and returned to normal (100/70mmHg or <90th percentile) only by the 6th week of illness. Serial urinalysis after discharge showed persistence of proteinuria and hematuria of ++ each, but complete resolution by 9th week. Repeat Echocardiography by 6th week still showed normal coronary arteries. Aspirin was changed to low dose (5mg/Kg/day) and subsequently stopped. His clinical condition has remained stable since discharge and is currently on follow up.

Discussion

This is the first report of Kawasaki disease presenting at an unusual age and with renal involvement from our centre. Our case fulfilled 5 of the clinical criteria for diagnosis of Kawasaki disease namely fever, exanthema, bilateral non exudative conjunctivitis, cervical lymphadenitis and desquamative changes of the hands and feet. Initially, the diagnosis was not suspected as typical features such as desquamation and lymphadenitis were lacking in the patient, but these appeared subsequently. It is well documented that clinical features of KD may not appear all at the same time and diagnosis often require sequential evaluation of patient¹².

A major challenge in the diagnosis of KD is the lack of a specific diagnostic parameter to confirm diagnosis. Some patients (up to 15%) with KD may not even fulfil the clinical criteria and may have atypical or incomplete KD characterised by presence of only two or three principal features with no other diagnostic or laboratory fea-

tures supportive of severe inflammation or coronary artery aneurysms^{1,4,12}. This can result in misdiagnosis/under diagnosis particularly if index of suspicion is low. The paucity of reports on KD in Nigeria and most of Africa may reflect the rarity of the disease in our environment; but underestimation of the actual disease burden due to non recognition is another possibility.

KD is generally a disease of the young, with 80% of cases occurring in children less than 5 years⁴. Unlike Sotimehin *et al* in Nigeria and Badoe *et al* in Ghana who reported KD in 3 and 4 year old children respectively^{8,9}, our patient presented at an unusual age of 14years. A few other reports across the world have also reported KD among atypical age group^{10,11}. Kara and Tezer *et al* reported it in a 30-day-old neonate¹¹ where as Rozo and colleagues observed the typical features of the disease in a 36-year-old man¹⁰. It was also reported in a 2-week old-neonate- the youngest age in the world so far¹². Hence irrespective of age, Kawasaki Disease should always be considered as a possible differential.

The exact cause of the disease is still unknown though an inciting agent, such as bacterial super antigen or a viral agent in a susceptible host may trigger an immune vasculitis which is typically multi systemic^{2,4,12}. Cardiac complication is the most life threatening sequelae of the disease, largely due to its effect on the coronary arteries^{2,4,12}. Fortunately, our patient had no echocardiographic evidence of coronary artery involvement at presentation and up to the time of last follow up echocardiography by six month. Predictive factors for coronary artery lesion (CAL) including marked leucocytosis (>30,000/mm³), elevated ESR (>101mm/hr), low hemoglobin (<10g/dl), prolong fever (>14days), hypoalbuminaemia and male gender have been described^{2,4}. Except for the latter, our patient had none of the above risk factors. Hence, it is not surprising that serial echocardiographic evaluation of his cardiac status remained normal. Some authors have observed the occurrence of severe coronary artery abnormalities in their patients such as giant aneurysms, thrombosis and myocardial infarction leading to death in some cases.¹¹

The observation of proteinuria, hematuria, elevated blood urea nitrogen and mild hypertension in our patient is a definite evidence of renal involvement. The pathogenesis of renal manifestation in KD is attributed to the vasculitic process^{1,4,12}, though other workers failed to demonstrate histopathologic evidence for this in their patients and suggested the possible role of immune mediated injury during the sub acute phase of the disease⁶. We did not do renal biopsy in our patient as it was considered unnecessary. This is because the patient had clinical and biochemical evidence of resolution of his renal function. The complete recovery of renal function in our case confirms earlier reports that renal involvement in KD is usually benign and self limiting^{1,5,7}.

Though intravenous immune globulin (IVIG) has been shown to reduce the risk of coronary artery lesion when given early at a dose of 2g/kg^{4,12}, it was not used for our patient due to non availability- a typical problem in many developing countries. Despite this limitation, our patient clinical condition remained normal and his echocardiographic picture did not deteriorate. However, he was given Acetyl Salicylic Acid (aspirin) which is also an integral component of management of KD that is recommended for use during the initial and convalescent stages of the disease^{2,5}.

Conclusion

Kawasaki disease can occur even in older children and may present with renal involvement which is self limiting. Since early diagnosis with institution of appropriate treatment can significantly reduce the risk of morbidity and mortality, clinicians should have high index of suspicion for KD to prevent misdiagnosis.

Conflict of interest: None

Funding: None

References

1. Tizard EJ. Complications of Kawasaki disease. *Current paediatrics*.2005; 15:62-68
2. Fulton DR, Newburger JW. Kawasaki disease. In: Keane JF, Lock JE, Fyler DC (eds). Nadas' Pediatric Cardiology. 2nd edition. Saunders, Philadelphia. 2006:401-413.
3. Omokhodion SI. Kawasaki disease. In: Azuibuke JC, Kanginieme KEO (eds): Paediatrics and child health in a tropical region, African Educational Services, Owerri.1999: 344-346.
4. Ahamed M Z. Kawasaki Disease: Diagnosis and management. In: Kumar KR, Prabhu S, Ahamed MZ(eds). IAP speciality series on Pediatric Cardiology.Jaypee Brothers Medical Publishers, New Delhi.2008:196-202.
5. Nandi M, Mondal R. Acute renal failure in a child with KD. *Eastern J Med*. 2010; 15:122-124
6. Mac Ardle BM, Chambers TL, Weller SD, Tribe CR. Acute renal failure in Kawasaki disease. *J R Soc Med*. 1983; 76(7):615-616
7. Bonany PJ, Bilkis MD, Gallo G, Lago N, Dennehy MV, Sosa del Valle JM et al. Acute renal failure in typical kawasaki disease. *Pediatr Nephrol*. 2002; 17(5):329-31
8. Sotimehin SA, Ogunlesi TA, Adekanmbi AF, Fetuga MB, Odumuyiwa EA, Olowu OA. Kawasaki disease in a Nigerian child-a case report. *Niger Med Pract*. 2010; 57 (4):
9. Badoe EV, Neequaye J, Oliver-Commey JO, Amoah J, Osafo A, Aryee I, Nyarko MY. Kawasaki disease in Ghana: Case reports from Korle Bu Teaching Hospital. *Ghana Med J*. 2011; 45 (1): 38-42.

-
10. Rozo JC, Jefferies JL, Eidem BW, Patrick JC. Kawasaki Disease in the Adult: A Case Report and Review of the Literature. *Tex Heart Inst J*. 2004; 31(2): 160-164.
 11. Kara A, Tezer H, Devrim I, Korkmaz E K, Karagoz T, Ozer S, Cengiz AB, secmer G. Kawasaki disease: A case report in extreme of paediatrics. *Infect Dis Clin Pract* 2006; 14:333-334.
 12. Takahashi M, Newburger JW. Kawasaki Disease (mucocutaneous lymph node syndrome). In: Allen HD, Driscoll DJ, Shaddy RE, Feltes TF (eds). *Moss and Adams' Heart Disease Infants, Children, and Adolescents including the fetus and young adult*. 7th edition. Lippincott Williams and Wilkins, Philadelphia. 2008: 1242-1256.