

Ujunwa AF  
Chinawa JM  
Obidike E  
Abah IU

## Caroli disease in a 2 month old Nigerian-A case report

DOI:<http://dx.doi.org/10.4314/njp.v40i4.12>

Accepted: 10th December 2012

Chinawa JM (✉)  
Ujunwa AF, Obidike E  
josephat.chinawa@unn.edu.ng  
Department of Paediatrics

Abah IU  
Department of Radiology  
University of Nigeria Enugu Campus;  
University Of Nigeria Teaching  
Hospital Ituku - Ozalla, Enugu.  
Enugu, Nigeria.

**Abstract** We present a rare and first case of Caroli Disease (CD) in a child who presents with abdominal distension, regurgitation of feeds, passage of greenish stools and fever, typical ultrasonographic and abdominal and x-ray findings. The purpose of presenting this case report is to highlight the distinctive manifestation of Caroli disease and to provide a concise report of this rare disease with the hope that

such information will help identify patients earlier in the course of their illness. This will add to medical literature by helping clinicians to know that this anomaly is treatable in a good setting and if detected early.

**Key words:** Rare disease; childhood; polycystic disease; liver disease; Nigeria.

### Introduction

Caroli's syndrome is a rare congenital disorder that involves intrahepatic bile duct ectasia and congenital hepatic fibrosis, frequently seen with concomitant autosomal recessive polycystic kidney disease (ARPKD).<sup>1</sup> Cystic lesions of the liver and bile ducts are classified as rare diseases. Polycystic kidney disease does not usually exist alone but can occur as a syndrome. Caroli syndrome consists of Caroli disease and congenital hepatic fibrosis.<sup>2</sup> It is Caroli disease if there is segmental dilatation of the large intrahepatic duct. Caroli disease is a rare disorder and often associated with autosomal recessive polycystic kidney disease.<sup>2</sup> The diagnosis depends on both histology and radiological findings. Treatment consists of symptomatic treatment of cholangitis by antibiotics, some endoscopic, radiological, surgical and drainage procedures. Liver transplantation seems the ultimate treatment for this disease. Prognosis is fairly good unless recurrent cholangitis and renal failure develops.

The purpose of presenting this case report is to note the distinctive manifestation of Caroli disease and to provide a concise report of this rare disease with the hope that such information will help identify patients earlier in the course of their illness.

This case report becomes necessary because there is no known report among infants in Enugu and it will also help the clinician to have a high index of suspicion and early referral to surgeons so as to avert numerous complications that follow it.

In addition, Caroli disease share some features with certain more commonly encountered conditions like

polycystic kidney disease, hepatoma or even intestinal obstruction, with which it could be confused with, hence the need to highlight specific features of Caroli disease?

### Case presentation

A two month old Ibo female, presented in the Children Out-Patient Department of University Of Nigeria Teaching Hospital with a history of abdominal distension and fast breathing since birth, regurgitation of feeds and passage of greenish stools of two weeks duration and fever of one week duration. Baby's illness started from birth when mother noticed abdominal distension which has since increased in size with regurgitation and vomiting of non billous material. There was also passage of greenish stools which is non- mucoid. Fever started after seven weeks of initial symptoms, high grade, continuous and transiently relieved by paracetamol.

Baby was delivered at term in a private hospital, cried immediately after delivery and weighed 3.5Kg.

This child had never been jaundiced at any time.

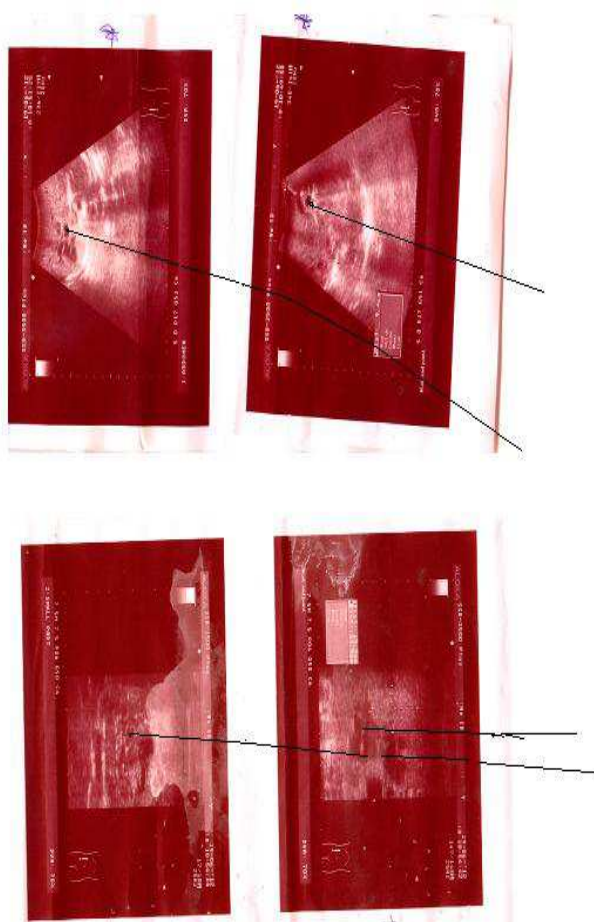
Examination findings revealed an acutely ill looking child with nasogastric tube in situ, febrile with distended abdomen with visible veins and multiple masses at the hypogastrim, left iliac fossa and left hypochondrium (mobile, the smallest measuring about 6cm at its widest diameter, the mass can be reached above). There is also hepatomegaly of 8cm below the right coastal margin, firm, smooth surface and blunt edge. Weight was 3.9kg

A diagnosis of Hepatoblastoma to consider polycystic

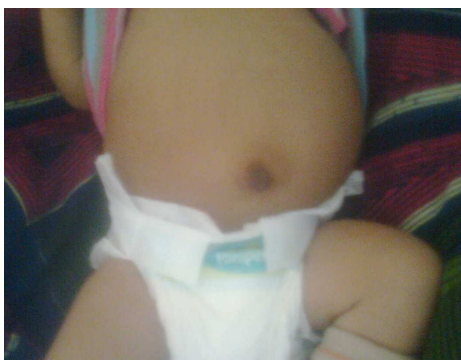
kidneys was made initially. Patient was admitted and the following investigations were requested: plain abdominal X-ray which showed increase hepatic shadows and chest x-ray which revealed no abnormality. Abdomino-pelvic ultrasound showed multiple non-obstructive dilated intrahepatic biliary tree and multiple pin sized bilateral renal cyst with "central dot sign" in the liver. These features are in keeping with paediatrics Caroli disease.

Liver function tests showed: Alkaline phosphatase 33U/L [25-92], Aspartate transaminase 32U/L [5-15] and Alanine transferase- 6U/L[3-15] which were all normal. Prothrombin time, serum albumin, and serum bilirubin were within normal limits. She has been referred to surgeons and is being worked up for surgical resection.

**Fig 1:** Ultrasonography of the liver and biliary tree .See areas of hyperechogenicity (Indicated by arrows) showing the typical central dot



**Fig 2:** Showing the infant with abdominal distension



## Discussion

Caroli disease and Caroli syndrome are very rare, with an estimated incidence of less than one case per 100,000 population.<sup>1</sup> Caroli syndrome (ectasia of the large and small bile ducts with congenital hepatic fibrosis) is more common than Caroli disease (ectasia of only the large bile ducts).<sup>2</sup> More than 200 cases of Caroli's disease have been reported in the literature and the incidence of Caroli's syndrome is more than the pure form of Caroli's disease.<sup>3</sup> Kiguli et al in South Africa reported a case with Caroli syndrome presenting as choleduchal cyst.<sup>4</sup> Much is not reported about this disease in Nigeria

Caroli's disease which is a component of Caroli syndrome was a first known distinct clinical entity reported by Jacques Caroli in 1958 in France.<sup>5</sup> He described two forms of the disease: The so called Caroli disease which is characterized by dilatation of larger intrahepatic bile duct with or without polycystic kidney and Caroli syndrome which is often associated with polycystic kidney disease, portal hypertension and eventual liver fibrosis.<sup>6</sup> Our patient had Caroli disease since she has no portal hypertension and liver fibrosis. Many authors believe that the two conditions are actually different stages of the same disease characterized by periportal fibrosis and ductal dilatation.<sup>7</sup> Unbalanced translocation between chromosome 3 and 6 explains the familial clustering and its association with polycystic kidney disease.<sup>8</sup> Caroli syndrome and Caroli disease are associated with renal involvement in 60% of cases and implies dilatation of collecting renal tubules. This index case also had renal involvement. In majority of patients with Caroli syndrome, portal hypertension will not be present or will appear only later in the disease evolution.<sup>9</sup> The late appearance of portal hypertension is due to the fact that the disease is progressive and dynamic.<sup>10</sup> The patient is usually asymptomatic but may develop complications later. In our case, the baby was diagnosed at a very young age. The fever, passage of greenish stools, regurgitation of feeds and non-biliary vomiting made us suspect possible pyloric stenosis, but the multiple cysts in the kidneys, hard liver and absence of shoulder sign in ultrasound made us downplay this suspicion. However these symptoms mentioned above may be due to cholangitis and sepsis which are common complications in Caroli disease. This is buttressed by the resolution of fever when the baby was started on antibiotics. It has also been noted in a study that patients with Caroli disease or Caroli syndrome may have a history of intermittent abdominal pain and fever, which reflects episodes of bile stasis leading to cholangitis.<sup>9</sup> The physical examination of enlarged hard liver and multiple masses made us suspect the diagnosis which was then confirmed by ultrasonography.

Hepatoblastoma is less likely here because it is rarely diagnosed at two months and it does not follow a turbulent course and usually seen as an incidental finding with absence of central dot sign and renal involvement.<sup>11</sup> Though bilirubin and Liver enzymes are normal in hepatoblastoma, alpha-feto proteins are elevated.

Unfortunately we could not do alpha -feto proteins in this index case due to financial constraint.

Ultrasonography is the initial investigation of choice.<sup>8</sup> The pure form shows diverticulum like sacculi of intra-hepatic biliary tree, more pronounced towards the center (central dot sign) and can be segmental or generalized.<sup>8</sup> This is akin to our patient who also had a “central dot sign” on ultrasound. Ozlem et al<sup>12</sup> noted that “intraluminal portal vein sign” which consists of portal vein radicles surrounded by the dilated bile duct is diagnostic of Caroli’s disease. The state of liver enzymes depend on the level of affection, for instance in some series it was noted that liver function was normal while that noted by Ozlem et al<sup>12</sup> showed shortened prothrombin time and elevated transferase enzymes. Liver function test was within normal ranges in this study.

Kidney may be normal or of variable echogenicity, depending on the extent of involvement by polycystic renal disease.<sup>8</sup> In our case, abdominopelvic ultrasound showed multiple cystic lesions in the liver and multiple bilateral pin sized cysts in kidney. These same findings were also corroborated by Rupali and colleagues who reported multiple and small cysts in the liver and kidneys respectively.<sup>5</sup> Computerized tomography is an invaluable adjunct that complements ultra-sound. It can identify cholangiocarcinoma and hepatic masses not identified by ultrasound. The diagnosis is more difficult to establish in the case of fusiform dilatations of the biliary tracts. Endoscopic retrograde cholangiopancreatography (ERCP) is the gold standard in this situation.<sup>9</sup> This shows communication between the sacculi and bile ducts and diverticulum-like sacculi of the intra-hepatic biliary tree.<sup>9</sup> Though ERCP is helpful in suggesting the need for further investigation, it has demonstrated difficulty in the visualization of the upper hepatic duct and may not give a specific diagnosis and thus ultrasonography is preferred.<sup>9</sup>

Congenital hepatic fibrosis is a histopathological diagnosis. Parada and colleagues<sup>8</sup> noted that histopathological intrahepatic bile duct ectasia and proliferation are associated with severe periportal fibrosis and confirm the congenital hepatic fibrosis component of “caroli’s syndrome”. Histopathology was not done for our patient since ultrasonography could still detect dilatation of larger intrahepatic bile duct.<sup>8</sup> It is pertinent to note that one can still make a diagnosis of Caroli disease without histopathology as ultrasonography still remains the gold standard.<sup>7</sup>

The treatment for Caroli’s disease includes supportive care with antibiotics for cholangitis and sepsis, ursode-

oxycholic acid for hepatolithiasis.<sup>13</sup> Surgical resection has been used successfully in patients with monobar disease. For patients with diffuse involvement, the treatment of choice is orthotopic liver transplantation.<sup>13</sup> Our patient was placed on antibiotics and is being prepared for surgery.

Complications from Caroli’s disease are cholangitis, sepsis, choledocholithiasis, hepatic abscess and cholangiocarcinoma later in life.<sup>13</sup> None of these is seen in this patient. Patil and co-workers<sup>13</sup> noted that after cholangitis occurs, a large number of patients will die within 5-10 years. The occurrence of hepatobiliary malignant transformation, explained by chronic inflammation of the biliary tree, has been reported in 7%-14% of patients. Death is related to liver failure or complications of portal hypertension.<sup>14</sup>

---

## Conclusion

Caroli’s Disease is indeed a rare congenital anomaly. Surgical correction offers good and long term results. In a resource poor country like ours, high index of suspicion, early diagnosis and timely referral are warranted so as to avert death.

*Limitation:* ERCP and histology were not done due to financial constraints.

*Consent:* Written informed consent was sought from the patient for publication of this case report and accompanying images.

## Authors’ Contribution

All the authors made substantial intellectual contributions to this case report CJM was involved in the preparation of the manuscript, revision of the article at various stages and preparation of the final draft. Other authors made substantial contributions preparation of the manuscript, revision and preparation of the final draft.

**Conflict of Interest:** None

**Funding:** None

---

## Acknowledgements

Our gratitude extends to the care giver and patient who were very cooperative.

Finally we thank the almighty God whose assistance and ideas through the course of this work is priceless.

---

## References

1. Jeong TK, Yoon JH, Jee MP, Myung JK, Young NP, Jae SL. Caroli’s Syndrome with Autosomal Recessive Polycystic Kidney Disease in a Two Month Old Infant. *Yonsei Med J* 2006; 47: 131
2. Karim B. Caroli’s Disease, A case series. *Ind J Paediatr* 2007;41:848-50
3. Nakanuma Y, Harada K, Sato Y, Ikeda H. Recent progress in the etiopathogenesis of pediatric biliary disease, particularly Caroli’s disease with congenital hepatic fibrosis and biliary atresia. *Histol Histopathol* 2010;252:223-35

4. Kiguli-Malwadde E, Kawooya MG. Choledochal cyst: an atypical presentation of Caroli's disease. *Central Afr J Med* 1996; 42:329-30.
5. Rupali V, Rajesh K. Caroli's syndrome: A case report. *Curr Pediatr Res* 2011; 15:59-60
6. Seth AK, Chawla Y, Dhiman RK, Gupta S, Suri S, Dilawari JB. Caroli's disease. a central dot means a lot. *Trop gastroenterol* 1997; 18:165-66
7. Keramidas DC, Kapouleas GP, Sakellaris G. Isolated Caroli's disease presenting as an exophytic mass in the liver. *Pediatr Surg Int* 1998; 13: 177-179
8. Parada L, Hallen M, Hagerstrand I, Tranberg KG. Clonal chromosomal abnormality in congenital bile duct dilatation. *Gut* 1999; 45:780-2
9. Levy AD, Rorhmann CA, Murakata LA, Lonergan GJ. Caroli's disease: radiological pattern and pathological correlates. *Am J Roentgenol* 2002; 179:1053-57
10. Gorka W, Lewall DB. Value of Doppler sonography in the assessment of patient with caroli disease. *J Clin Ultrasound* 1998; 26:283-7
11. Stoker JT. Hepatoblastoma. *Semin diagn pathol* 1998; 11:136-43
12. Ozlem Y, Yusuf B. Clinical characteristics of Caroli's syndrome. *World J Gastroenterol* 2007; 13: 1934-37
13. Ananthakrishnan AN, Saeian K. Caroli's disease: identification and treatment strategy. *Curr Gastroenterol Rep* 2007 ;9:151-5.
14. Patil S, Das HS, Desai N, Manjunath SM, Thakur BS, Sawant P. Caroli's syndrome- a rare cause of portal hypertension. *J Assoc Physicians India* 2004; 52: 261