

Adeboye MAN
Adegbeye OA
Yusuf AS
Saka AO
Akintola MA
Ayeni AS
Adebayo AB
Olorunsola S
Buhari T

Massive subgaleal haematoma in a 5 year old child – A case report

DOI:<http://dx.doi.org/10.4314/njp.v40i2.19>

Accepted: 18th August 2012

Adeboye MAN (✉)
 Adegbeye OA, Saka AO, Akintola MA
 Ayeni AS, Adebayo AB, Olorunsola S
 Department of Paediatrics & Child
 Health

Yusuf AS, Buhari T
 Department of Surgery
 University of Ilorin Teaching Hospital,
 Ilorin, Kwara State
 PMB 1459, Ilorin.
 Email: adeboyeman@yahoo.co.uk
adeboye.man@unilorin.edu.ng
 Tel: +2348033841268

Abstract Subgaleal haematoma (SH) is a collection of blood between the bony skull and the loose connective tissue. It is almost a diagnosis confined to the neonatal age group with very few occurring beyond the age. Presentation could be sudden or chronic as deterioration in the cardio pulmonary status, shock, skin changes, airway obstruction and neurological sequelae.

While assisted delivery with birth trauma are recognized causal factors in the neonate, trauma to the

head and blood related disorders have been reported to be major causes in older children and adults. Usually, the Small SH resolves spontaneously while the massive ones require active management; often with neuro surgical intervention. It also needs identifying the cause so as to treat and prevent a recurrence.

We present a case of massive SH in a 5 year old mentally subnormal child with seizure disorder with a favourable outcome.

Introduction

The subgaleal space is the virtual space that exists within the scalp between a thin fibrous sheet known as the galea aponeurotica and a very tough fibrous covering of the skull bone called the periosteum.¹⁻³ It is a space that extends from the forehead to the nape of the neck and also down the sides of the head to a point just above the ears, in other words more or less the area over which the scalp covers the skull.³⁻⁴ It has been documented that infants can lose 50% to 75% of their blood volume into the space thus responsible for significant morbidity and mortality when it is not recognized early.⁵ Subgaleal haemorrhage is caused by the rupture of the emissary veins which are connections between the dural sinuses and scalp veins.³⁻⁶ It is seen in the neonatal period often following vacuum extraction. It may be associated with birth trauma, trauma to the head, child abuse and coagulation disorders.⁷ Reports have been made about its occurrence following swing related head injury, plucking of the hair and herbalist's therapeutic intervention in a woman with puerperal psychosis.⁸⁻¹⁰ Most small SH resolve spontaneously but the rare massive ones often require neurosurgical intervention in the form of needle aspirations or open drainage with compressive head dressing.

Case report

A 5-year old girl presented with recurrent convulsions of five years and progressive enlargement of the head of five weeks prior to presentation. The child had focal, tonic- clonic convulsions involving right upper and lower limbs on the second day of life necessitating neonatal hospitalization for eleven days.

Seizures became atonic when child was about three and half year old with associated sudden falls of frequency of 5-10 per day. There was significant associated delay in neuro- developmental milestone as child did not sit until one and a half years and was only able to vocalise bi-syllabic words (baba and mama). Mother defaulted follow up clinic when child was 2 years old claiming she noticed some improvement though she claimed to have continued the drugs for child.

About five weeks prior to presentation mother noticed progressive enlargement of the head which started first as a small swelling at the occiput following a fall when the child hit her head on a concrete floor during a seizure episode. No apparent bleeding from the skull or any craniofacial orifices. The head size increased progressively and by the fourth week child could no longer control the head. (Figure 1a) There was associated painful

discomfort and excessive crying in the child. There was no fever.

At onset of illness child was taken to a private hospital where syrup paracetamol and ampiclox were administered. No past history of blood transfusion and her history was not suggestive of sickle cell disease.

She is the third child in a monogamous family of 6. Father is an electronics technician while the mother retails household items. Both parents have secondary school education certificate.

Examination revealed child to be conscious, irritable, severely pale, anicteric, in painful distress, not dehydrated, afebrile (36.2°C, axillary temperature), had no finger clubbing, peripheral lymph node enlargement or pedal oedema.

Her occipito-frontal circumference (OFC) was 62.5cm (markedly enlarged), Weight was 12kg, (67% of the expected) and length was 100cm (93.5% of the expected). The head was massively enlarged, translucent, tender, fluctuant with shining scalp with scanty hairs. There was cranio-facial disproportion. No wound on the scalp. The swelling extends anteriorly to the supraorbital ridge, laterally to the zygomatic arch and the hairline posteriorly. (Figure 1a and 1b)

Fig 1a: Enlarged fluctuant head

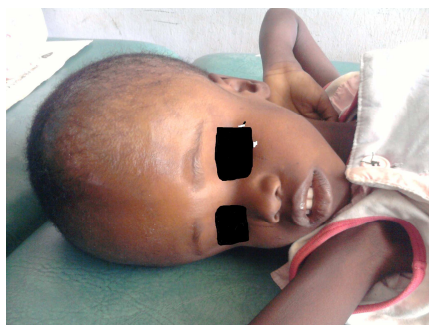
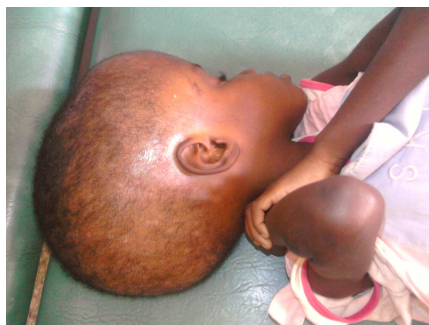
Fig 1b: Posterior view of head



Child was conscious with significant boggy macrocephaly, No signs of raised intracranial pressure, no sign of any cranial nerve deficit, tone was normal and deep tendon reflexes were intact.

Respiratory rate was 45 breaths/minute, chest was symmetrical, trachea was central, chest expansion was uniform bilaterally and percussion notes were resonant globally. No added sounds.

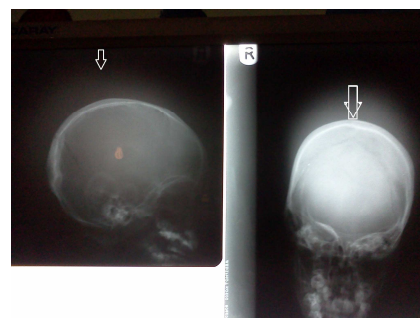
Pulse was regular and of moderate volume, pulse rate was 102 beats/minute, no pulse deficit, blood pressure was 90/50 mmHg, No precordial bulge, apex beat was located at the left fourth intercostal space, mid-clavicular line. The heart sounds heard were first and

second only, no murmur.

The abdomen was flat, soft and moves with respiration. No area of tenderness. No palpable mass. No organ enlargement and bowel sounds were present and normoactive.

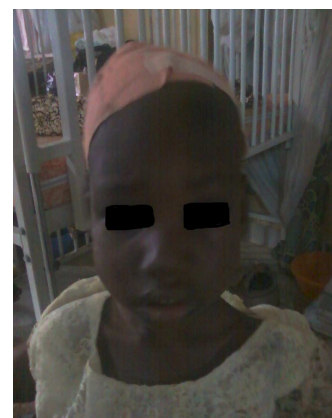
An assessment of a massive subaponeurotic abscess in a 5 year old with seizure disorder was made. Massive subgaleal haematoma was also considered. An urgent PCV showed anaemia (17%), Electrolytes and Urea and Random blood glucose were essentially normal. White Blood cell Count revealed reversal of Neutrophil:Lymphocyte ratio for age. Her skull x-ray showed massively enlarged head with no involvement of the cranial vault. (Figure 2). Scalp ultrasound showed extensive fluid collection in the subgaleal space from frontal to occipital region with some internal echo strandings. Fluid thickness to bone surface was 9.8cm. Clotting Time was 7min, PT-14sec (control=13), PTTK-33sec (control=35sec). Ultrasound guided aspiration yielded 10mls of uniformly bloody aspirate. A reviewed diagnosis of massive subgaleal haematoma was made.

Fig 2: X ray AP & lateral views



Action taken included counseling of the mother on the need for admission and the possible line of treatment. She was transfused with 200mls of packed cells, commenced on IV Ceftriaxone 100mg/kg /day, daily OFC measurement, the Neurosurgical unit was invited for co-management. On the second day, Post transfusion PCV=27%, she was commenced on serial aspiration (a total of 2.65 Litres) and serial blood transfusion (of 600mls) over 16 days of admission during which the OFC reduced to 49cm. Appropriate dose of sodium valproate was commenced, and significant seizure control was achieved. Child was discharged after 18 days on admission. Has attended follow up on three occasions and the head circumference has remained constant. (Figure 3)

Fig 3: Just before discharge



Discussion

The presence of recurrent convulsions since the second day of life found in this child was not related to the presence of the SH as at that age, however it might have been due to a missed asphyxial insult to the child. Studies have shown that convulsions in the first 48-72 hours of life are mostly due to birth asphyxia.¹¹ The presence of significantly delayed developmental milestones is another pointer to the possibility of such insult.¹² The global developmental delay in this child which manifested as delayed motor, social and speech development suggests that child might probably be mentally subnormal thus suffered some form of neglect from the mother; this may be the reason for late presentation as such children are prone to abuse and neglect.¹³ Though, only one episode of fall was reported but in view of the reported frequency of the drops, the falls could have been multiple thus resulting in more bleed with each.

The systematic drainage of over 2.5litres and transfusion of only 600mls of blood over the hospitalization period was instrumental to the survival of the child. The accumulated blood within the subgaleal space in this child is well above the estimated upper limit of the total blood volume of the child which under normal condition should be 1,032mls (51-86mls/kg).¹⁴ The slow progressive nature of the SH in this case typified progression of a chronic subdural haematoma.¹⁵ While most small SH resolved with conservative management, surgical evacuation with close drainage of the subgaleal space and application of compressive head dressing remained the effective treatment of massive subdural haematoma.^{4,9}

Emphasis on optimal control of seizures is important in order to prevent recurrent episode of the SH. The occurrence of this massive SH would have been nipped in the

bud if the mother had presented earlier.

The apparent improvement in the compliance of the mother as regards the follow up might have been due to the survival of the child despite the poor state of the child at admission.

Conclusion

The subgaleal space is a highly distensible space that is wide enough to accommodate even more than the total blood volume of a child. The management of massive SH requires prompt identification, systematic drainage of the accumulated blood with adequately planned blood transfusion. Successful management of a massive SH boosts the confidence of the care givers in the health workers and improves compliance to orthodox medical care. Multidisciplinary approach to the management of massive SH is highly encouraged. It is also recommended that in the evaluation of post neonatal children with a fluctuant macromegaly who have atonic seizures and perhaps mental retardation, subgaleal haematoma should be considered so that early recognition and prompt treatment be given.

Conflict of interest: None

Funding: None

Acknowledgement

We appreciate all the members of the Department of Paediatrics and Child health, University of Ilorin Teaching Hospital, who took part in the management of the child.

References

- Adams-Chapman I, Stoll BJ. The Cranium In: Kleigman RM, Jenson HB, Behrman RE, Stanton BF eds Nelson Textbook of Pediatrics, Saunders Elsevier, Philadelphia, 2007: 714-5
- Moore KL, Dalley AF. Head In: Clinically Oriented Anatomy 4th ed. Lippincott Williams and Wilkins Publishers, Philadelphia, 1999 :857-875
- Mangurten H. Birth Injuries In: Martins RJ, Fanaroff AA, Walsh MC Eds Fanaroff and Martin's Neonatal-Perinatal Medicine, 8th ed. Mosby, Philadelphia, 2006: 532-557
- Antón J, Pineda V, Martin C, Artigas J, Rivera J. Posttraumatic subgaleal hematoma: a case report and review of the literature. *Pediatr Emerg Care*. 1999 Oct;15(5):347-90
- Coroners act 2003. Findings of an Inquest 2009-2010. South Australia Available at www.courts.sa.gov.au, accessed on 12th of August, 2011.
- Hutspardol S, Chuansamrit A, Soisamrong A. Spontaneous Subgaleal Hemorrhage in a Girl with Impaired Adrenaline-Induced Platelet Aggregation. *J Med Assoc Thai* 2010; 93 (5): 625-8
- Rohyans JA, Miser AW, Miser JS. Subgaleal haemorrhage in infants with haemophilia: report of two cases and review of the literature. *Paediatrics* 1982; 70:306-7.
- Faber MM. Massive subgaleal haemorrhage: A hazard of playground swings. *Clin Pediatr (Phil)* 1976; 15(4):384-5.
- Shehu BB. Massive chronic subgaleal haematoma. *Brit J Neurosurg* 2002; 16(4): 396-397
- Hamlin H. Subgaleal haematoma caused by hair-pull. *JAMA* 1968;204:339.
- Perlman JM, Tack ED, Martin T, Shackelford G, Amon E. Acute systemic organ injury in term infants after asphyxia. *Am J Dis Child* 1989;143:617-20
- Levene MI. The asphyxiated newborn infant. In: Levene MI, Lilford RJ. Fetal and neonatal neurology and neuro-surgery. Edinburgh: Churchill Livingstone 1995: 405 - 26.
- Cooke P, Standen PJ. Abuse and disabled children: Hidden needs? *Child Abuse Review* 2002; 11(1):1-18.
- Osberg IM. Blood volume In: Hay WW, Levin MJ, Sondheimer JM, Deterding RR eds Current Pediatric Diagnosis and Treatment. Lange Medical books, New-York; 2005: 1341
- Sudhakar N, Simpson BA. Massive subgaleal haematoma *Brit J Neurosurg* 2002; 16(4): 394-395