

Okposio MM
Unior MO

Pneumomediastinum and subcutaneous cervical emphysema: unusual complications of childhood pneumonia

DOI:<http://dx.doi.org/10.4314/njp.v41i1.16>

Accepted: 8th September 2012

Okposio MM (✉)
Unior MO
Department of Paediatrics,
Mariere Memorial Central Hospital
Ughelli, Delta State, Nigeria
Mariere Memorial Central Hospital
Ughelli, Delta State,
Nigeria.
Tel: +2348034042120
Email: mattokmatok@yahoo.com

Abstract The occurrence of pneumomediastinum and subcutaneous cervical emphysema as complications of childhood pneumonia is very unusual. They results most often from respiratory manoeuvres that produce high intrathoracic pressure. Although they are largely benign, pneumomediastinum can cause compression of major blood vessels in

the mediastinum resulting in life threatening complications. Therefore, adequate knowledge of these conditions and their proper management is very important for clinicians.

Keywords: Subcutaneous Cervical Emphysema, Pneumomediastinum, Childhood, Pneumonia

Introduction

Pneumomediastinum, otherwise known as mediastinal emphysema refers to the presence of free air within the mediastinum while subcutaneous cervical emphysema refers to the presence of air in the subcutaneous tissue of the neck.¹ These clinical entities are uncommon in paediatric practice with an overall prevalence ranging between 1 in 800 and 1 in 42000 patients seen at the emergency department.² Mediastinal and subcutaneous cervical emphysema may occur spontaneously, or secondary to trauma or pathological disease³, with gastrointestinal and respiratory diseases most commonly implicated.^{4,5}

The respiratory disease commonly associated with pneumomediastinum and subcutaneous cervical emphysema is bronchial asthma.⁶ Pneumonia, though a very common childhood respiratory system morbidity known to be associated with several complications⁷ is very rarely implicated in the occurrence of pneumomediastinum and subcutaneous cervical emphysema.^{8,9} Although, these clinical conditions are largely benign, pneumomediastinum can cause compression of major blood vessels in the mediastinum resulting in life threatening complications.¹⁰ It was therefore important to report this case in order to highlight its clinical presentation, radiological features and the management options.

Case Report

O.B, a 20- month old boy was brought to our emergency department with a history of increasing difficulty with breathing and progressive anterior neck swelling which started a few hours before presentation. He had had a fever, cough and mild difficulty with breathing for about

four days for which the parents were administering medication bought over the counter. He has not been diagnosed with asthma and this was the first episode of difficulty with breathing. There was no history of chest wall trauma or of any gastrointestinal disorder.

On physical examination, the patient was noted to be very irritable and markedly dyspnoeic, with flaring of the alae nasi and subcostal and intercostals recessions. He was febrile with a temperature of 38.7°C. He had a diffuse anterior neck swelling extending to both clavicular areas and the upper chest wall with crepitus on palpation. (Fig 1) His respiratory rate was 56 breaths per minute and an oxygen saturation of 89% on room air. There were crackles on both middle and lower lung zones. His heart rate was 160 beats per minute and heart sounds were normal. In addition, there was an associated “mediastinal crunch” (Hamman’s Sign). Chest x-ray showed a widespread perihilar and bibasal opacities in keeping with bronchopneumonia. It also revealed streaky and bubbly lucencies in the mediastinal, supraclavicular and chest wall region confirming subcutaneous emphysema and a pneumomediastinum (fig 2). Laboratory investigation showed an elevated white cell count of 20,000 mm³, the electrolytes and urea were essentially normal. Other investigations done included HIV testing for both patient and mother after appropriate pre-test counselling and the results were negative

Fig 1
Photograph showing diffuse anterior neck swelling due to subcutaneous emphysema

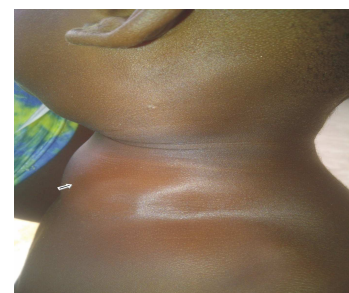
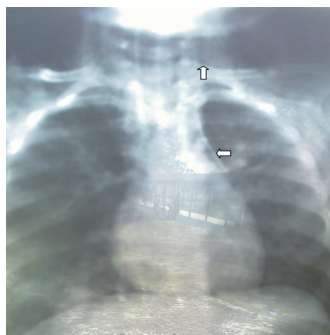


Fig 2

Chest radiograph of a 20 month-old boy showing subcutaneous cervical emphysema and pneumomediastinum (white arrows)



On the basis of the history, examination and radiological findings, a diagnosis of bronchopneumonia complicated by pneumomediastinum and subcutaneous cervical emphysema was made. He was admitted into the paediatric ward and commenced on intravenous antibiotics and high flow oxygen. He made remarkable improvement with complete resolution of subcutaneous emphysema on the 4th day of admission. He was discharged on the 7th day after completing the full course of intravenous antibiotics and followed up on a monthly basis for eight months without recurrence and was subsequently discharged from clinic.

Discussion

Pneumomediastinum and subcutaneous cervical emphysema are unusual complications of childhood pneumonia.^{8,9} Most cases of pneumomediastinum result from alveolar rupture with subsequent air leak into the surrounding bronchovascular sheath.¹¹ Because the mean pressure in the mediastinum is always less than the pressure in the pulmonary parenchyma, the free air tends to move centripetally along the vascular sheaths, perhaps facilitated by the pumping action of breathing. The air dissects to the hilum, and spreads into the mediastinum or through the loose mediastinal fascia to the subcutaneous tissues of the neck.¹²

Pneumomediastinum and subcutaneous cervical emphysema can be caused by a large and diverse group of factors especially respiratory manoeuvres that produce high intrathoracic pressure such as valsalva manoeuvre, coughing, vigorous crying and forceful retching or vomiting¹³. Respiratory tract infections (e.g bronchopneumonia, bronchiolitis, laryngotracheitis) have been implicated in the development of pneumomediastinum and subcutaneous cervical emphysema especially in association with asthma,² and the organisms that had been found in previous reports include *mycoplasma pneumonia*, *influenza A (H1N1)* virus and *Pneumocystis jiroveci* (in the HIV exposed or infected children).^{14,15,16} Although there was a clear evidence of an infection in our patient giving the presenting symptoms and the elevated white cell count, we could not however isolate the particular organism due to laboratory inadequacies. Obstructive lung diseases (e.g Asthma, foreign body aspiration, bronchopulmonary dysplasia) especially in intubated and mechanically ventilated patient are also risk factors

for pneumomediastinum and subcutaneous cervical emphysema⁶

The clinical diagnosis is based on the symptom triad of dyspnoea, chest pain and subcutaneous emphysema.¹⁷ It is also based on Hamman's sign which consist of a crunching rasping sound, synchronous with the heart beat and best heard over the precordium with patient on the left lateral decubitus position.¹⁸ Our patient met most of the diagnostic features except for pain which we could not confirm because of the age of the patient; however, we think the patient had pain because of the irritability that was present at presentation.

The diagnosis of pneumomediastinum and subcutaneous cervical emphysema can be made clinically; however, it is pertinent that imaging studies be done for confirmation. Chest radiography (although not invariably) reveal a pneumomediastinum and co-existing disease (e.g pneumonia, pneumothorax). Another diagnostic tool is chest computerized tomographic scan which may be used to diagnose pneumomediastinum not visualized on chest radiography. It has been reported that up to 30% of patient presenting with mild pneumomediastinum could be missed with chest radiography alone.¹⁹

The management of pneumomediastinum and subcutaneous cervical emphysema is largely conservative as spontaneous absorption of air occurs within two week². This process however can be enhanced by breathing high concentration of oxygen. Reassurance, observation and analgesia as well as treating the underlying cause are all that is needed in most cases. Our patient responded on the fourth day of admission following antibiotics and oxygen therapy. Although recurrence rate is reported to be low,²⁰ we still followed up our patient for a reasonable period of time.

Conclusion

Pneumomediastinum and subcutaneous cervical emphysema in this index case constituted an unusual but very important complication of childhood pneumonia which is amenable to conservative treatment. It was therefore important to report this case to raise awareness amongst clinicians so as to avoid unnecessary surgical decompression that may worsen the situation.

Conflict of interest: None

Funding: None

Acknowledgement

We want to sincerely appreciate Dr Damijo Henry and the unit Nurses for their dedication and support.

References

1. Maunder RJ, Pierson DJ, Hudson LD. Subcutaneous and mediastinal emphysema: pathophysiology, diagnosis and management. *Arch Intern Med* 1984; 144: 1447-1453
2. Chalumeau M, Le Clainche L, Sayeg N et al. Spontaneous pneumomediastinum in children. *Pediatr Pulmonol* 2001; 31: 67-75
3. Lee CY, Wu CC, Lin CY. Etiologies of spontaneous pneumomediastinum in children of different ages. *Pediatr Neonatol* 2009;50: 190-195
4. Schmidt GB, Bronchorst MW, Hartgrink HH et al. Subcutaneous cervical emphysema and pneumomediastinum due to a lower gastrointestinal tract perforation. *World J Gastroenterol* 2008; 14: 3922-3923
5. Egbagbe E.E, Elusoji S.O. Pneumomediastinum and subcutaneous emphysema associated with asthma exacerbation. *J Pak Med Assoc* 2006; 56: 287-289
6. Damore DT, Dayan PS. Medical causes of pneumomediastinum in children. *Clin Pediatr* 2001; 40: 87-91
7. Durbin JW, Stille SC. Pneumonia. *Pediatr rev* 2008;29:147-160
8. Chih-Yung C, Kin-Sun W, Tsung-Chieh Y et al. Asthmatic versus Non asthmatic spontaneous pneumomediastinum in children. *Asian Pac. J. Allergy Immunol* 2005; 23: 19-22
9. Yalaburgi SB. Subcutaneous and mediastinal emphysema associated with childhood measles. *S Afr Med J* 1980; 38: 521-525
10. Miguil M, Chekairi A. Pneumomediastinum and pneumothorax associated with labour. *Int. J Obstet. Anesth* 2004; 13: 117-119
11. Zylak CM, Standen JR, Barnes GR et al Pneumomediastinum revisited. *Radiographics* 2000; 29: 127-134
12. Macklin CC. Transport of air along sheath of pulmonic blood vessel from alveoli to mediastinum: clinical implication. *Arch Intern Med* 1939; 64: 913-926
13. Panacek EA, Singer AJ, Sherman BW, Prescott A et al. Spontaneous pneumomediastinum: Clinical and natural history. *Ann Emerg Med* 1992; 101: 1265-1267
14. Vazquez JL, Vazquez I, Gonzalez ML, et al. Pneumomediastinum and pneumothorax as presenting signs in severe Mycoplasma pneumonia pneumonia. *Pediatr Radiol* 2007; 37:303-306
15. Hasegawa M, Hashimoto K, Morozumi M et al. Spontaneous pneumomediastinum complicating pneumonia in children infected with 2009 pandemic influenza A (H1N1) virus. *Clin Microbiol infect* 2010; 16:195-199
16. Rosen DJ, Blasberg RC, Ashton CP et al. Spontaneous pneumomediastinum in pneumocystis pneumonia and Acquired Immunodeficiency Syndrome. *The Internet Journal of Pulmonary Medicine*. 2009; 10: DOI: 10.5580/20c2
17. Weissberg D, Weissberg D. Spontaneous mediastinal emphysema. *Eur J Cardiothoracic Surg* 2004; 26: 885-888
18. Hamman L. Spontaneous mediastinal emphysema. *Bull John Hopkins Hosp*. 1939; 64:1-21
19. Kaneki T, Kubo K, Kawashima A et al. Spontaneous pneumomediastinum in 33 patients: yield of chest computed tomography for diagnosis of the mild type. *Respiration* 2000; 67: 408-411
20. Fiorelli A, Messina G, Capaccio D et al. Recurrent spontaneous pneumomediastinum: a rare but possible event. *J Thorac Dis* 2012; 4: 431-433