

Ndu Ik
Chinawa JM
Chikani M
Ibekwe R
Aronu AE
Edelu BO
Asinobi I

Dandy Walker malformation (variant): late presentation with childhood blindness

DOI:<http://dx.doi.org/10.4314/njp.v42i1.17>

Accepted: 1st October 2014

Ndu Ik (✉)
 Department of Paediatrics,
 Enugu State University Teaching
 Hospital

Chinawa JM, Ibekwe R, Aronu AE
 Edelu BO, Asinobi I
 Department of Paediatrics,

Chikani M
 Department of Surgery,
 University of Nigeria Teaching
 Hospital, Ituku Ozalle Enugu, Nigeria.

Abstract: We present a rare case of Dandy Walker Syndrome in a child who presents with complaints of frontal headache, neck pain, fever, progressive visual impairment and multiple generalized tonic clonic seizures, inability to stand and urinary incontinence. Given the clinical and neuro-imaging findings, the diagnosis of Dandy Walker Variant was made. Post surgical recovery (Ventriculo peritoneal shunt) was

remarkable. Unfortunately he never regained sight. The purpose of presenting this case report is to highlight the distinctive manifestation of Dandy walker syndrome to enhance early diagnosis, prompt intervention and better outcome

Key words: Dandy Walker syndrome; congenital brain malformation; childhood blindness; hydrocephalus

Introduction

Dandy Walker Syndrome is a rare congenital malformation of the central nervous system. It results from a developmental failure of the roof of the fourth ventricle which occurs during embryogenesis. It has been reported in identical twins as well as in one identical twin but not the other, suggesting a combination of genetic and environmental influences. Molecular genetic studies have detected deletion of cerebellar genes Z1C1 and Z1C4³. Incidence is 1:25,000-30,000 in the Western hemisphere³ and 1:100,000 in Saudi Arabia. It is commoner in females though male preponderance has been reported in India^{3,4}. Local incidence rates are not known.

The association of vermian hypoplasia, posterior fossa cyst and hydrocephalus was first reported by Sutton in 1887 but Dandy and Black fan were the first to describe the condition as a clinical triad in 1914. The primary defect was thought to be atresia of the foramina of Luschka and Magendie. This was however refuted by Benda, in 1954, who concluded that the primary anomaly was maldevelopment of the vermian and not necessarily due to foraminal atresia, because some autopsy cases had patent foramina and introduced the eponym 'Dandy Walker Syndrome'⁷.

The term Dandy Walker Syndrome or complex doesn't represent a single entity but refers to a spectrum/continuum of posterior fossa cystic malformations. Currently Three types have been described: Dandy-

Walker malformation, Dandy Walker variant, and mega cisterna magna. The classic triad in Dandy Walker malformation consists of dysgenesis of the cerebellar vermis, cystic dilatation of the fourth ventricle, enlargement of the posterior fossa. Dandy-Walker variant is less severe than Dandy Walker malformation and is characterized by variable hypoplasia of the cerebellar vermis, cystic posterior mass, and no enlargement of the posterior fossa. An enlarged cisterna magna, normal vermis and 4th ventricle are seen in mega cisterna magna.

Pathogenesis involves failure of regression of the embryonic anterior membranous area of the rhombencephalic roof which leads to cystic dilatation and vermian dysgenesis³. The fourth ventricle is grossly misshapen because it is a membrane-wrapped cyst that extends into the foramen magnum as far as C2. The cyst can also herniate upwards through the tentorial hiatus elevating the torcula herophili and lateral sinuses, causing a functional aqueductal stenosis with resultant hydrocephalus¹⁰.

The clinical features depend on the effects produced by the cyst, the presence or absence of hydrocephalus and associated anomalies. Infants may present with progressive skull enlargement and slow motor development. Older children with hydrocephalus may present with signs of raised intracranial pressure³. Patients could be asymptomatic as seen in people with Dandy Walker variant who live their entire lives without any symptoms.

Dandy-Walker syndrome often occurs in patients with PHACE syndrome and an emerging class of diseases called ciliopathies. Diagnosis is by CT scan which can distinguish between hydrocephalus associated with Dandy-Walker and hydrocephalus associated with other etiologies. MRI is performed for detailed evaluation of Dandy-Walker malformation lesions and complications after the diagnosis is suspected using computed tomography (CT) and ultra-sound¹⁵. USS is used for prenatal diagnosis and it is particularly used for postnatal follow-up studies of hydrocephalus¹⁵. Treatment involves surgery, management of associated problems and genetic counseling. This case is being reported because of its rarity and the need for a high index of suspicion in clinical practice. Early identification and appropriate intervention can significantly improve quality of life.

Case report

Eleven year old male who was referred from Federal medical centre Asaba with complaints of continuous fever, frontal headache, early morning effortless vomiting and neck pain that progressed to retraction of 8 weeks duration. There were also multiple seizures, tonic clonic with loss of consciousness, progressive visual impairment as revealed by fundoscopy, that progressed to blindness with aggressiveness, out of school with normal development milestone. He eventually couldn't stand and also developed urinary incontinence over the last 2/52. General examination revealed a fully conscious but very irritable child, anthropometry (especially occipito-frontal circumference) was within normal limits. CNS exam revealed Positive meningeal signs, Pupils 5mm dilated reacting sluggishly to light, Fundoscopy revealed bilateral papilloedema, optic atrophy. There was global hypertonia and hyperreflexia and truncal ataxia earlier and Blood pressure was elevated (150/130 mmHg) lately. Initial Diagnosis of Post Meningitic Hydrocephalus was made to rule out an SOL. Routine investigations: FBC, SEUCR, Urinalysis, RVS (negative) were essentially normal, CT Scan report: Dandy Walker Variant. See fig 1. Visual acuity showed no perception to light. Given the history and unique clinico-radiological features, the diagnosis of Dandy Walker (variant) was made. Given the history and unique clinico-radiological features, the diagnosis of Dandy Walker (variant) was made. Treatment was with phenobarb, Antibiotics Rocephin because meningitis was suspected. Decongestants was given to reduce the raised intracranial pressure since fundoscopy revealed bilateral papilloedema, though hydrallazine was used to reduce the blood pressure but it still remained high. Ventriculo peritoneal shunt was done on the 9th day, Post surgical condition was satisfactory. Seizures stopped, blood pressure normalized and patient subsequently became ambulant and followed up in the clinic, however visual acuity still showed no perception to light. Unfortunately he never regained sight.

Visual impairment initially was not taken serious by mother till he became completely blind and required assistance to move around

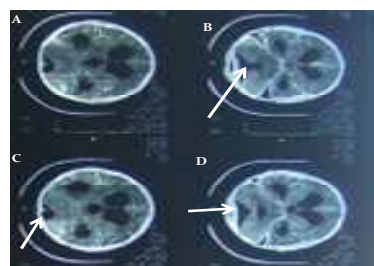


Fig 1: CT Scan report of the patient

Discussion

Dandy Walker Syndrome is a rare congenital malformation of the Central Nervous System¹. It could arise as a genetically sporadic disorder and this may be the cause of the index case. However molecular genetic studies to detect deletion of cerebellar genes Z1C1 and Z1C4 were not done because of laboratory limitations. It is reported to be commoner in females, though the present case is male. Other predisposing factors include first trimester exposure to rubella, cytomegalovirus, toxoplasmosis, warfarin, alcohol, and isotretinoin¹⁵. We could however not ascertain if our patient was exposed to these variables above in utero.

Some patients may be asymptomatic with normal intracranial pressure or they may have only mild unsteadiness of gait or intellectual impairment until the syndrome is activated by head trauma or a systemic infection. Our patient developed the symptoms at the age of 11 years after a febrile illness. Post meningitic occlusion of the foramina of Luschka and Magendie has been reported³ and this may have complicated the underlying congenital abnormality which led to the development of the clinical features at presentation in the index patient.

The classical triad of hydrocephalus in an older child whose sutures are supposed to have fused includes dementia, urinary incontinence, inability to walk or ataxia. We noted two out of the triad in our case. These are due to pressure effects of long standing hydrocephalus and the minimum requirements for the shunt replacement or endoscopic third ventriculostomy operations are, the presence of at least two components of the clinical triad, presence of ventriculomegaly, and normal opening pressure of CSF. The raised blood pressure was a compensatory mechanism to maintain cerebral perfusion and the eventual progression to neck retraction was possibly an ominous sign of coning. Visual impairment initially was not taken serious by mother till he became completely blind and required assistance to move around. The optic nerve is very fragile and is easily damaged by raised intracranial pressure. The optic artery is in the centre of the optic sheath and resultant optic ischemia and optic atrophy lead to irreversible blindness and this occurred in the index case. Early surgical intervention may have arrested this.

Diagnosis is by CT scan which can distinguish between hydrocephalus associated with Dandy-Walker and hydrocephalus associated with other etiologies¹⁵. The CT scan for the index case revealed tri-ventricular dilatation and communication between the fourth ventricle and

cyst at the level of petrous bone with mastoid air cells.

In a resource poor country like ours, high index of suspicion, early diagnosis and timely referral are key notes

Conclusion

Dandy walker syndrome is a rare anomaly. Early surgical intervention may offer a good and long term results.

<p>Conflict of interest: None Funding: None</p>

References

- Alexiou GA, Prodromou N. Dandy Walker Malformations. In: Manto M, Schmahmann JD, Rossi F, Gruol DL, Koibuchi N, editors. Handbook of the cerebellum and cerebellar disorders. 1st ed. Netherlands. Springer Netherlands; 2013.
- Haslam RHA. Congenital anomalies of the central nervous system. In: Nelson WE, Behrman RE, Kliegman RM, Arvin AM, editors. Nelson textbook of paediatrics. 15th ed. Philadelphia. WB Saunders Company; 1996.
- Albright AL, Pollack IF. Principles and Practice of Pediatric Neurosurgery. 2nd ed New York: Thieme; 2011.
- Ohaegbulam SC, Afifi H. Dandy-Walker Syndrome: incidence in a defined population of Tabuk, Saudi Arabia. *Neuroepidemiology* 2001;20:150-2.
- Ozgen T, Acikgoz B. CSF dynamics in Dandy-Walker syndrome. *Acta Neurochirurgica* 1990;104:54-8
- W.E. Dandy, K.D. Blackfan. Internal hydrocephalus: an experimental, clinical, and pathological study, *Am. J. Dis. Child.* 1914; 8:406–82.
- Barrack S. Dandy-Walker syndrome [Internet]. 2011 . Available from: <https://jneurology.wordpress.com/article/dandy-walker-syndrome>. Assesed on 21st march,2014
- Benda CE. The Dandy-Walker syndrome or the so-called atresia of the foramen of Magendie. *J Neuropathol Exp Neurol* 1954;13:14-29.
- Alam A, Chander BN, Bhatia M. Dandy walker variant: Prenatal diagnosis by ultrasonography. *Med J Armed Forces India.*2004;60:287–9
- Incesu L, Khosla A. Imaging in Dandy-Walker syndrome [Internet]. 2013 [cited 2014 Mar 21]. Available from: <http://emedicine.medscape.com/article/408059-overview>
- Thamburaj VA. Atlas of Instruments in Otolaryngology Head and Neck Surgery. 1st ed New Delhi: JP Medical Ltd; 2012
- Dandy walker variant. http://www.rightdiagnosis.com/d/dandy_walker_variant/intro.htm
- Metry DW, Dowd CF, Barkovich AJ, Frieden IJ. The many faces of PHACE syndrome. *J. Pediatr.* 2001;139:117–23.
- Badano Jose L, Norimasa M, Beales PL, Katsanis N. The Ciliopathies: An Emerging Class of Human Genetic Disorders. *Annual Review of Genomics and Human Genetics.* 2006;7:125–48.
- Hamid HA. Review article: Dandy Walker Malformation. *Egypt. J. Hum Genet.* 2007;8:115-20
- Dandy Walker syndrome. [Internet] [cited 2014 Apr 4] Available from: <http://www.medgyan.com/index.php?option=symptoms&deId=1090>
- Manhant S, Manhant P, Biswas R. *BMJ Case Reports*2012;doi:10.1136/bcr.01.2012.5686
- Taskin MM. Normal pressure hydrocephalus is a treatable syndrome. *Düşünen Adam.* 2008; 2145-58