

Peterside O
Duru CO
Anene N

Harmful traditional practices in a newborn: A case report

DOI:<http://dx.doi.org/10.4314/njp.v42i2.16>

Accepted: 17th November 2014

Peterside O (✉)
Duru CO, Anene N
Department of Paediatrics and Child
Health, Niger Delta University
Teaching Hospital, Okolobiri,
Bayelsa State, Nigeria.
Email: docolyemen@yahoo.com

Abstract: Ninety-nine percent of the nearly four million newborn deaths occur in developing countries with newborn deaths remaining relatively invisible and neglected¹. In these countries, traditional attitudes and practices dominate newborn care and are often hazardous². As most births and newborn deaths in developing countries occur outside health care facilities, a reduction in neonatal mortality may depend significantly on interventions involving adaptation of traditional care behaviours practiced at home³. However, despite the importance of traditional practices in the newborn period, little is known about the impact of these

practices on newborn health². We herein present a case of an eighteen day old female who was rushed to the hospital with severe wasting, recto-vaginal prolapse and septic umbilical cord resulting from repeated traditional homecare practices by her mother and grandmother. This case highlights the impact of harmful traditional home care practices on newborn health and emphasizes the urgent need for public enlightenment campaigns and other policy decisions and interventions aimed at reducing this societal menace.

Keywords: Harmful traditional practices, newborn, neonatal morbidity, neonatal mortality

Introduction

Neonatal mortality which accounts for about two thirds of infant mortality is a useful indicator of the socio-economic development of an area⁴. Insufficient pre, peri and post natal care negatively affects child health especially in developing countries³. Though ninety nine percent of the nearly four million newborn deaths occur in developing countries⁵. Until the twenty first century, newborn health was virtually absent from policies, programmes and research in these countries¹.

Culture is considered a dynamic factor which plays an important role in health and disease with cultural values, attitudes, beliefs and behaviours affecting lifestyle and health⁶. Some traditional practices are harmful to the child because they constitute physical and mental abuse of children and are deleterious both to the individual as well as the process of national development⁶. Several studies^{7,8} have shown that some traditional neonatal care practices which vary with culture may cause infections, anaemia, hypothermia and hypoglycaemia thus increasing the risk of morbidity and mortality in this age group. In developing countries like Nigeria, traditional attitudes and practices dominate newborn care and are often hazardous⁵. We hereby present a case of a female neonate who was a victim of harmful traditional practices which resulted in severe morbidity and eventual mortality. This case highlights the urgent need for intervention pro-

grammes to reduce this societal menace which will ultimately improve neonatal and infant survival rates.

Case

AB was an 18 day old female rushed by father and Paternal Aunt into the children emergency ward of the Niger Delta University Teaching Hospital with complaints of abdominal swelling since birth, recurrent seizures of ten days duration, inability to suck of nine days, inability to pass stool of seven days, protrusion of the umbilicus, vagina and rectum of two days duration and fast breathing which started six hours prior to presentation.

Abdominal swelling was said to be initially more on the left side but gradually progressed to involve the entire abdomen. She passed meconium on the first day of life and thereafter had a normal bowel opening of about twice daily. Seizures were generalized tonic clonic in nature, each episode lasted for about five minutes and aborted spontaneously. She had about two episodes per day with no loss of consciousness. On the 10th day of life, she stopped sucking from her mother's breast and only accepted feeds from a feeding bottle until a day prior to presentation when she stopped feeding altogether. Seven days prior to presentation, she was noticed to have stopped passing stool which necessitated maternal grandmother to commence abdominal massage

which resulted to progressive recto-vaginal prolapse. Fast breathing was noticed after she was forcefully fed with a cup and spoon. There was no history of bluish discoloration of the body. On systemic review, there was weight loss, reduced urinary output and vomiting.

Symptoms were initially managed at home with several episodes of abdominal massage, administration of several water based concoctions and incisions on the face and abdomen. She was also given several unknown drugs bought over the counter and ground red pepper was applied to the umbilicus daily. When her condition continued to deteriorate, father decided to bring her to the hospital.

Pregnancy was unsupervised and uneventful. Delivery was at term, supervised by a traditional birth attendant. She was initially on breast milk and water until the tenth day of life when infant formula was commenced. She was fed with about 30 to 40mls of infant formula three times daily. Feeds were diluted with unboiled rain water. She was the first child of unmarried parents. Her mother is a 17 year old SS3 student while father is a 21 year old commercial motor cyclist with secondary level of education.

On examination, she was wasted with prominent ribs, and zygomatic bone as well as loss of subcutaneous fat (fig 1). She was in respiratory distress, febrile with fresh scarification marks on her face, trunk and abdomen. She was dehydrated with a dry buccal mucosa. Her weight was 1.65kg, occipitofrontal circumference 32cm, length 45cm.

She was lethargic, had neck stiffness with fisting and global hypertonia. She also had tachypnea and tachycardia. There was abdominal distension with prominent veins and an inflamed umbilical hernia (fig 1). The abdomen was tense and the organs were difficult to palpate. There was protrusion of the rectum and vagina with necrosis of the rectal mucosa (fig 2).

Fig 1: Wasting (loss of subcutaneous fat) with inflamed umbilicus

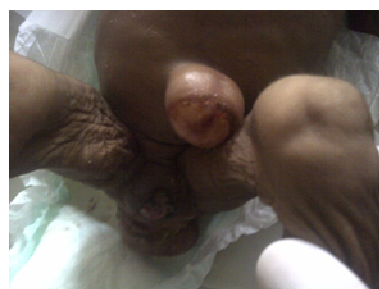
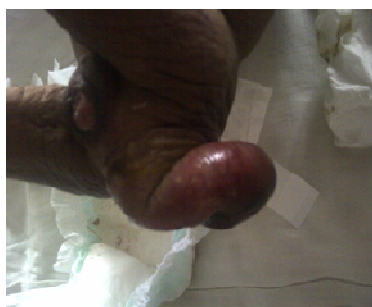


Fig 2: Prolapsed vagina and rectum



She was managed as a case of overwhelming sepsis with failure to thrive, aspiration pneumonia, septic umbilical hernia and gangrenous recto-vaginal prolapse. Results of serum electrolytes, urea and creatinine showed hyponatremia of 123mmol/l, hyperkalaemia of 13.1mmol/l, uraemia of 36.5mmol/l and raised creatinine of 451umol/l. Full blood count showed a normal packed cell volume of 48% with leukocytosis of $17.5 \times 10^9/L$. Her random blood sugar was normal and she was non-reactive to rapid HIV test.

The protruded organs were dressed with normal saline, she was placed on intranasal oxygen, intravenous ceftriazone and metronidazole and a nasogastric tube was passed and retained to decompress the abdomen. Anti-tetanus serum was prescribed but was not given as parents did not provide the drug prior to her demise. She was reviewed by the surgeons who made the same diagnosis and planned surgery when she was more stable. A fluid challenge was also done but she still failed to make urine. Her clinical condition remained poor until she died after 13 hours 45 minutes of admission.

Discussion

This case highlights the negative impact of harmful traditional practices on neonatal morbidity and mortality. The harmful traditional practices in the index case included abdominal massage, administration of herbal concoctions, scarification marks and unsterile umbilical cord care. This is similar to findings by Darmstadt and Saha⁹ who reported that more than 96% of caregivers interviewed at Dhaka Shishu hospital and Matlab Health Complex both in Bangladesh practiced oil massage on their newborns irrespective of socio-economic status and place of residence. Akcan et al¹⁰ in Turkey also reported a case of a five year old mentally retarded boy who died from duodenal perforation as a result of blunt abdominal trauma and ingestion of concoctions given to him by his father and step-mother.

Similar to the scarifications given to the index case, Beser et al³ reported that a quarter of mothers of infants in Izmir, Western Turkey, cut their babies noses, backs of ears, backs or limbs in order to cure jaundice. Opara et al¹¹ reported that 62.4% of mothers attending three health centres in Yenagoa, Southern Nigeria practiced unhygienic cord care which included application of antibiotic ointments and herbs. Joel-Madewase et al¹² in Osogbo, Western Nigeria, reported harmful cord care practices to include fomentation with hot water, lantern, and knife as well as application of menthol containing creams. Thakur and Kumar¹ also reported that 74% of mothers in Ganda community, India applied paste of mustard oil and turmeric powder on their babies umbilical stumps.

Since the mother and grandmother who were caring for the index case did not present to the hospital, their reasons for using the earlier mentioned care practices

were not ascertained. Damstadt and Saha⁹ however reported perceived benefits of infant massage among their subjects as being prevention of infections and hypothermia. Opara et al¹¹ reported low maternal education, delivery outside health facilities and low parental social class to be significantly associated with unsterile cord care while Joel-Madewase et al¹² identified ignorance as the number one reason given by their subjects for poor cord care. These reasons may be applicable to the index case who was born into a low socio-economic household with an un-married teenage mother with incomplete secondary education and delivery which was supervised by a traditional birth attendant who may have very little knowledge of umbilical cord care. Ofili and Okojie¹³ carried out a study to assess the role of traditional birth attendants in maternal health care in Oredo, Edo State, Nigeria. Preparations used for umbilical cord care by these traditional birth attendants included methylated spirit, herbal concoctions, animal dung, flies, cow urine, dry heated sand and engine oil. The influence of the maternal grandmother in the index case also, cannot be overemphasized as she was the one who repeatedly performed abdominal massage in spite of all the complications that arose.

The index case brings to attention harmful traditional child care practices which constitute physical abuse of children. Common risk factors for child abuse in the index case included low socio-economic class, unmarried parents, and a teenage mother¹⁴⁻¹⁵. The fact that the child was not brought to the hospital by her primary

care givers is also suggestive of child abuse¹⁰. Rather it was her father and Aunt who visited and subsequently rushed her to the hospital when they noticed her poor clinical state.

Conclusion

Traditional practices have been found to dominate newborn care in developing countries². While some of these practices may not have any harmful effect on health, others do⁶. Mothers not equipped with sufficient knowledge about child care who use traditional child care methods may cause harm to their children's health³. It is therefore recommended that these practices should be investigated, the useful ones should be preserved while the harmful ones should be discarded. There is an urgent need to educate mothers and other key family members on early neonatal care. The roles of community health actors such as mothers, mothers-in-law, husbands, and traditional birth attendants should be taken into consideration in intervention programmes. There is also need for intervention programmes like provision of health facilities in rural areas as well as employment of more health workers to man these facilities. The role of female education and poverty alleviation cannot be overemphasized.

Conflict of interest: None

Funding: None

References

1. Thakur N, Kumar A. A study on delivery and newborn care practices in urban slums of Ganda Community. *Antrocom Online J Anthropol* 2012; 8(1): 33 – 38.
2. Devkota MD, Bhatta MR. Newborn care practices of mothers in a rural community in Baitadi, Nepal. *Health Prospect* 2011; 10: 5 – 9.
3. Beser A, Topcu S, Coskun A, Erdem N, Geliskan R, Ozar D. Traditional child care practices among mothers with infants less than 1 year old. *Deuhyo Ed* 2010; 3(3): 137 – 145.
4. Ekure EN, Ezeaka VC, Iroha EO, Egri-Okwaji MTC. Neonatal mortality of inborns in the neonatal unit of a Tertiary Centre in Lagos, Nigeria. *Niger Ot J Hosp Med* 2005; 15(2): 55 – 58.
5. Lawn J, Cousens S, Bhutta Z, Darmstadt G, Martinez J, Paul V. Why are 4 million newborn babies dying each year. *Lancet* 2004; 364: 399 – 401.
6. Ameh CO. Harmful traditional practices in Nigeria and measures for eradication: An educology of home education. *Int J Educol* 2002; 16(1): 1 – 10.
7. Marsh DR, Darmstadt GL, Moore J, Daly P, Oot D, Tinker A. Advancing newborn health and survival in developing countries: a conceptual framework. *J Perinatol* 2002; 22(7): 572 – 576.
8. Winch PJ, Alam MA, Akther A, Afroz D, Ali NA, Ellis AA. Bangladesh PROJAHNMO study group. Local understanding of vulnerability and protection during the neonatal period in Sylhet District Bangladesh: a qualitative study. *Lancet* 2005; 366(9484): 478 – 485.
9. Darmstadt GL, Saha SK. Traditional practice of oil massage of neonates in Bangladesh. *J Health Popul Nutr* 2002; 20(2): 184 – 188.
10. Akcan R, Arslan MM, Kaliszan M, Batuk G. Fatal child abuse-maltreatment syndrome; a case report. *Rom J Leg Med* 2011; 19: 287 – 290.
11. Opara PI, Jaja T, Dotimi DA, Alex-Hart BA. Newborn cord care practices amongst mothers in Yenagoa Local Government Area, Bayelsa State, Nigeria. *Int J Clin Med* 2012; 3: 22 – 27.
12. Joel-Madewase VI, Oyedeji OA, Elemile PO, Oyedeji GA. Cord care practices of South-Western Nigerian mothers. *Int J Trop Med* 2008; 3(2): 15 – 18.
13. Ofili AN, Okojie OH. Assessment of the role of traditional birth attendants in maternal health care in Oredo Local Government area, Edo State, Nigeria. *J Comm Med Prim Health Care* 2005; 17(1): 55 – 60.
14. Capelleri JC, Eckenrode J, Powers JL. The epidemiology of child abuse. *JAMA* 2000; 100(8): 496 – 497.
15. Jones ED, McCurdy K. The links between types of maltreatment and demographic characteristics of children. *Child Abuse Neglect* 1992; 16(2): 201 – 215.