

**Ikobah JM**  
**Ngim OE**  
**Adeniyi F**  
**Ekanem EE**  
**Abiodun P**

## Paediatric endoscopy in Nigeria humble beginning

DOI:<http://dx.doi.org/10.4314/njp.v42i2.15>

Accepted: 6th January 2015

Ikobah JM (✉)  
 Ekanem EE  
 Department of Paediatrics,

Ngim OE  
 Department of Surgery,  
 University of Calabar Teaching  
 Hospital, Calabar,  
 Cross River State, Nigeria.  
 Email: joanikoba@gmail.com

Adeniyi F  
 Department of Paediatrics,  
 Lagos University College Hospital,  
 Lagos State, Nigeria

Abiodun P  
 Department of Paediatrics,  
 University of Benin teaching Hospital,  
 Benin City, Edo State, Nigeria.

### Abstract: Introduction

Paediatric gastroenterology has become an established subspecialty in the last five decades in developed and some developing countries. Endoscopy is the cornerstone of this sub-specialty. In Nigeria, it is still at its infancy stage, though with increasing local interest. This is a report of the first Paediatric Endoscopy Workshop in Nigeria organized as a pre-conference by the Paediatric Association of Nigeria (PAN) and the Nigerian Society of Paediatric Gastroenterology, Hepatology and Nutrition (NISPGHAN).

*Aim:* The aim of the conference was to promote and create awareness on paediatric gastroenterology as a subspecialty and introduce participants to the practice of paediatric endoscopy.

*Method:* This was a two day pre-conference workshop. Paediatricians, paediatric residents and nurses were in attendance. One International and three National resource persons were on ground to impart the needed knowledge and skills. Training involved didactic lectures, hands-on sessions using manikins and three live sessions involving the upper gastrointestinal tract.

*Results:* There were 40 attendees on day 1: 22 (55%) paediatric

residents, 12 (30%) consultant paediatricians and six (15%) nurses. Day 2: 22 (52%) paediatric residents, 12 (29%) consultant paediatricians and eight (19%) nurses.

Three children (two females and one male) had upper GI endoscopy (with biopsy done in two cases) during the pre-conference workshop as live sessions. They were aged eight, nine and 16 years. Indications for endoscopy were recurrent haematemesis in an eight year old female patient and recurrent upper abdominal pain in the other two patients (a male and a female). Gastritis was found in the two patients and this was confirmed histologically in one of the patients.

*Conclusion:* The training stirred up participant's interest in this subspecialty of paediatrics. It brought to fore the need for paediatric endoscopy to be developed in Nigeria. The procedure should be performed at tertiary centres at this stage of our development and the cost of it covered by the National Health Insurance Scheme. Four training centres to aid interested paediatricians and paediatric trained nurses acquire the needed skills are recommended.

**Keywords:** Paediatric endoscopy, Calabar, Nigeria.

### Introduction

The human desire to peer inside the body was the driving force in the development of endoscopy. The field of gastroenterology began with the Philip Bozzini's crude, candle-powered lightleiter in 1805<sup>1</sup> and blossomed with the introduction of flexible gastrointestinal endoscopy by Basil Hirschowitz in the late 1950s<sup>1</sup>. The first national gastroenterology society was established in Germany in 1895, shortly after this the American Gastroenterology Society was established in 1897<sup>1,2</sup>. However, it

took many years for the sub-specialty to be recognized in paediatrics. Fueled by the application of gastrointestinal endoscopy in children, paediatric gastroenterology began in the early 1960s<sup>2</sup>. The sub-specialty of paediatric gastroenterology, hepatology and nutrition was borne out of a clinical need to provide optimal care to children. The first society of paediatric gastroenterology was founded in Europe in 1967 and held its first meeting in 1968<sup>1-3</sup>. It has emerged as one of the most diversified medical – surgical practices in modern medicine with the subsequent development of smaller instruments for

gastrointestinal tract (GIT) endoscopy in the 1990s. Diagnostic and therapeutic paediatric endoscopic procedures are now the standard of care. The most frequently performed, mainly diagnostic, procedures are oesophagogastroduodenoscopy and colonoscopy<sup>4</sup>. Wireless capsule endoscopy (CE) or double balloon enteroscopy for investigation of the small intestine can also be performed. On the other hand, therapeutic procedures, such as polypectomy, retrieval of foreign bodies, percutaneous endoscopic gastrostomy (PEG) placement, endoscopic retrograde cholangiopancreatography (ERCP) or ligation of esophageal varices can now be performed even in the neonatal period. In contrast to adults, most endoscopic examinations in children are usually performed under deep sedation or general anaesthesia to reduce emotional stress caused by separation from parents and the preparation for the procedure itself.<sup>4</sup>

Paediatric gastroenterology is at its infancy stage in many parts of Africa<sup>5,6</sup>. In South Africa, it has only recently been registered by the Health Professions Council of South Africa (HPCSA)<sup>5</sup>. In Nigeria, paediatric endoscopy is an emerging field and data on this subject at present is scanty<sup>6</sup>. Paediatric endoscopy offers both diagnostic and therapeutic benefits though in many parts of Africa, this is largely carried out by the adult gastroenterologist and the lower gastrointestinal endoscopy seems to be an exclusive domain of the surgeons<sup>7,8</sup>. All these are due to few trained and certified Paediatric gastroenterologists. With the formation of the Nigerian Society of Paediatric Gastroenterology, Hepatology and Nutrition (NIPSGHAN) in 2012, more paediatricians are indicating interest in this sub-specialty. This is a report of what may be considered the beginnings of hands-on training in paediatric endoscopy in Nigeria.

## Report

The Paediatric Endoscopy training held in the city of Calabar, Cross River state, south-south Nigeria on 20<sup>th</sup> and 21<sup>st</sup> of January 2014 at the University of Calabar Teaching Hospital and Asi Ukpo Medical and Diagnostic centre in Calabar. The training held as a pre-conference workshop of the annual scientific meeting of the Paediatric Association of Nigeria (PAN) meeting in conjunction with the Nigerian Society of Paediatric Gastroenterology, Hepatology and Nutrition (NIPSGHAN). The training drew participants from all over Nigeria. The workshop was advertised at least four months before the date of commencement and interested participants indicated interest. There were 12 paediatricians, 22 paediatric residents and six nurses in attendance on the first day and eight nurses on the second day including the number of paediatricians and paediatric residents who were present on the first day. Resource persons included one international resource person from South Africa and three national resource persons. The aim of the conference was to promote and create awareness about paediatric gastroenterology as a subspecialty with emphasis on the need for paediatric endoscopy in the care of patients who may require this for optimum care.

The training involved didactic lectures, hands-on training using manikins and live sessions. The lectures focused on pertinent topics including: introduction to gastrointestinal endoscopy (brief anatomy of the upper GI, description of instrument, and procedure), indications for upper and lower GI endoscopy, endoscopy assessment, sedation and monitoring, introduction to diagnostic and therapeutic endoscopy and management of gastrointestinal emergencies. The nurses also obtained training on patient preparation, aftercare and maintenance of equipment in the endoscopy unit. There was also hands-on training using manikins which afforded all participants the opportunity to have a feel of the training process. Three live sessions involving the upper gastrointestinal system was carried out (two on the first day and one on the second day).

## Case reports

Three cases involving the upper GI endoscopy were done on children aged eight, nine and 16 years (two females and one male respectively). Indications for the endoscopy were recurrent haematemesis in the eight year old female patient and recurrent upper abdominal pain in the other two patients. Informed consent was obtained from the parents after the procedure was explained to them and their children. The children had the procedure performed after an overnight fast. The procedures were performed by trained paediatric and adult GI endoscopists. An Olympus Optera 170 Video paediatric gastroscope and a Karl storz video gastroscope were used to perform the procedures. All procedures were done on an outpatient basis. Two endoscopy nurses were present in the endoscopy room to assist with the procedures. This was performed after insertion of a reliable venous access, with monitoring of vital signs and oxygen saturation. Conscious sedation was administered by the anaesthetist using intravenous midazolam and propofol at appropriate doses. Xylocaine pharyngeal spray was also used. Multiple fragmented biopsies were taken from the antrum, fundus and duodenum in the 16 year old patient and from the mid and distal oesophagus, antrum, fundus and duodenum of the eight year old patient and sent for histology. No complications were recorded in the three procedures.

---

## Results

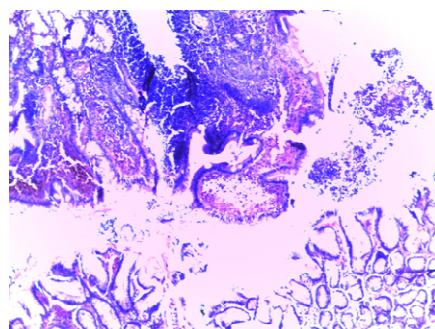
### Case 1

Gastroscope on the 16 year old male with history of recurrent upper abdominal pain for four months. Gastroscope showed pre-pyloric ulcers with extensive oedema of the surrounding mucosa in the stomach, erosions on the greater curvature and multiple ulcers in duodenal bulb with exudates (Fig 1a). Histology showed sections of pyloric-antral to early duodenal type epithelium, focal collection of lymphocytes, plasma cells and neutrophils in the submucosa mainly, with a spill over into the mucous membrane. No atypia was noticed. Findings were in keeping with chronic gastritis. Fig 1b.

Fig 1a

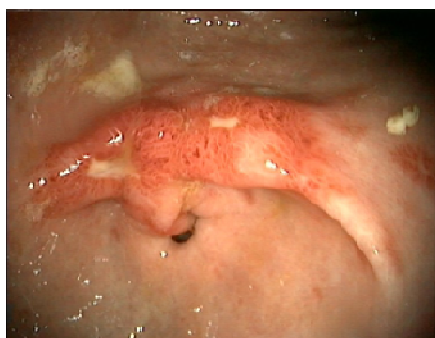

Fig 1b



### Case 2

An eight year old female with history of recurrent upper GI bleeding. She had two previous gastroscopy done on her which showed multiple haemorrhagic lesions in the second and third parts of the duodenum and this was the third following treatment. The gastroscopy was normal.

### Case 3

A nine year old female who presented with history of epigastric pain for two weeks and was managed for gastritis. Findings at endoscopy showed multiple erythematous spots in the pylori antrum and streaks of erythema radiating to the pylorus. No ulcers, nor gastric erosions.

## Discussion

Paediatric endoscopy offers both diagnostic and therapeutic benefits though special instrumentation is required<sup>1-4</sup>. Gastrointestinal diseases such as chronic abdominal pain, vomiting and diarrhoea are common all around the world<sup>9</sup>. Finding causes of gastrointestinal-problems leads to more efficient treatment and consequently decreases morbidity and mortality rates<sup>9</sup>.

Endoscopy is the best method for the diagnosis of most of these diseases and its application in children is increasing<sup>10,11</sup>. The diagnosis of gastritis was confirmed following histologic findings on the 16 year old patient who had biopsy specimen sent for histology (Fig 1b) and for the third patient with recurrent upper GI bleeding the gastroscopy done on her helped to confirm cure following treatment. Diagnostic indications for endoscopy includes recurrent abdominal pain, upper GI bleeding, chronic diarrhoea, malabsorption, caustic soda ingestion, unexplained anaemia, hematochasea/melena

stools Therapeutic indications for endoscopy include conditions such as; oesophageal varices eradication, foreign body removal, dilatation of oesophageal and upper GI strictures, PEG/feeding tubes, Mallory-Wiess syndrome and upper GI bleeding control<sup>11,13</sup>.

High sensitivity of endoscopy in the diagnosis of diseases and lack of radiation are important advantages of endoscopy in the care of patient<sup>13</sup>. There is an urgent need to develop this sub-specialty in Nigeria as there are studies done which have shown the prevalence of *Helicobacter pylori* infection ranging from 66.3% to 69% in the childhood population<sup>8,9</sup>. Other GIT problems are rife in this population. It may well be that children in Nigeria, like their counterpart elsewhere, have inflammatory bowel disease, coeliac disease and other gastrointestinal diseases which require endoscopy but the diagnosis are missed due to lack of expertise and appropriate equipment. The cost of gastrointestinal endoscopy in Nigeria is high and most patients are unable to pay for these services which most of the time is offered by the private sector. Cost of anesthesia in the paediatric age group also makes it even more expensive for the patients. The average cost of paediatric upper GI endoscopy in Nigeria is in the range of 200 to 250 US dollars while the lower GI endoscopy is 250 to 300 US dollars. This is beyond the reach of most parents in a country where 70% of the population live below the poverty line. There is therefore need for government subsidy in this regard.

As far as the safety of the procedures is concerned, most studies have generally found that upper GI endoscopies are safe regardless of age<sup>16-18</sup>. There are also suggestions that simple diagnostic endoscopies can be performed safely in the primary care setting, leaving secondary care units to concentrate on those patients requiring sedation, who are acutely ill, and who require therapeutic procedures<sup>16</sup>. Despite these positive findings, endoscopy does carry some risks. In a study by Quine et al<sup>18</sup> out of 13, 036 patients undergoing endoscopy, there were seven deaths, and this was suspected to have been an underestimation owing to the reliance on self reporting by doctors. Another study<sup>17</sup> reported significant complications and deaths from diagnostic oesophageal gastroduodenoscopy in 1 per 1000 and 1 per 10,000 procedures respectively. Patients' sex, age, or preference for sedation or endoscopist did not affect the morbidity rate. The United Kingdom National Confidential Enquiry into Patient Outcome and Death<sup>19</sup> report of 2004 identified a low mortality from therapeutic endoscopy, with the exception of percutaneous endoscopic gastroscopy (PEG), which had a mortality of 6%.The report made many recommendations to improve the structure and process of therapeutic endoscopy, including the importance of careful selection for PEG insertion and endoscopic retrograde cholangiopancreatography (ERCP), and the imperative of endoscopy for gastrointestinal haemorrhagebeing undertaken only by experienced endoscopists. Currently there is no study in Nigeria on the safety or risk of gastrointestinal endoscopy. The Federation of International Societies of Pediatric Gastroenterol-

ogy, Hepatology, and Nutrition (FISPGHAN) is analyzing and developing the implementation of Pediatric Endoscopy worldwide and aims to introduce a standardized curriculum for trainees and training the trainers<sup>20</sup>. Thomson et al<sup>21</sup> has shown the advantages of an intensive training by virtual endoscopy training.

the establishment of centres of excellence in Paediatric Endoscopy in Nigeria and Sub-Saharan Africa. Meanwhile, paediatric endoscopy should be done only at tertiary centres at this stage of its development in Nigeria.

**Conflict of interest:** None

**Funding:** None

## Recommendations

There is a need to make Paediatric Gastroenterology a sub-specialty by the National Postgraduate Medical College. Public-Private Partnership is advocated for the development of this sub-specialty in Nigeria. This will enhance training of sub-specialists and provision of the much needed facilities which the Government alone cannot provide, as in our index cases. Also, we recommend a subsidized cost for endoscopy in children to improve access to the service. We strongly recommend

## Acknowledgement

The authors will like to acknowledge the management of University of Calabar Teaching Hospital and Asi Ukpo Medical and Diagnostic Centre, Calabar for graciously granting the use of their endoscopic suites for the pre-conference training. We also acknowledge Karl Storz, Nigeria and JNCI Limited, Nigeria for the technical support they provided during this workshop.

## References

- Gilger, Mark A. Gastroenterologic endoscopy in children: past, present and future. *Curr Opin Paediatr* 2011; 13: 429-434
- Haight M, Thomas DW. Paediatric gastrointestinal endoscopy. *Gastroenterologist* 1995; 3(3):181-186
- Walker-Smith J, Walker W. The Development of Paediatric Gastroenterology: A Historical Overview. *Paediatr Res* 2003; 53 : 706 – 715
- riedt M, Welch S. An update on pediatric endoscopy. *Eur J Med Res* 2013 18:24
- Nel ED. A brief review of the history of paediatric gastroenterology. *S Afr Gastroenterology review* 2013: 16-18
- Ngim OE, Ikobah JM, Ukpabio I, Basse GE, Ekanem EE. Paediatric Endoscopy in Calabar, an Emerging Trend- Challenges and Prospects: A Report of two Cases. *EE IOSR J Dent Med Sci* 2014; 13: 28-30
- Irabor DO. Surgical gastrointestinal endoscopy in Ibadan, Nigeria. *Niger J Surg Res* 2006; 8:161-162
- Mudaun HMY, El Tahir MA, Suleiman SH, Eltaybe NH, Gamer NH, Abdalha FA et al. Paediatric Gastrointestinal endoscopy: experience in a Sudanese university hospital. *East Mediterr Health J* 2009;15:1027-1031
- El-Mouzan, MI, Abdullah AM, Al-Sanie AM, Al-Khalifah SI. Pattern of gastroesophageal reflux in children. *Saudi Med J* 2001;22:419-422.
- Agbakwuru EA, Fatusi AO, Ndu-bula DA, Alatisie OI, Arigbabu OA, Akinola DO. Pattern and validity of clinical diagnosis of upper gastrointestinal disease in south-west Nigeria. *Afr Health Sci* 2006; 6: 98 -102.
- Okello TR. Upper gastrointestinal-endoscopic findings in adolescents at Lacor hospital, Uganda. *Afr Health Sci* 2006; 6: 39-42.
- Walker WA, Goulet O, Kleinman RE, Sherman PM, Schneider BL, Sanderson IR. Pediatric Gastrointestinal Disease, Pathophysiology, Diagnosis, Management. 4th Edn., BC Decker, Hamilton 2004: 388-394.
- El-Mouzan, M.I., I.A. Al-Mofleh, A.M. Abdullah and R.S. Al-Rashed. Indications and yield of upper gastrointestinal endoscopy in children. *Saudi Med J* 2004; 25: 1223-1225.
- Aduful HK, Aeder SB, Darko R, Baako BN, Clegg-Lamptey JNA, Nkrumah KN. Upper gastrointestinal endoscopy at the Korle Bu Teaching hospital, Accra, Ghana. *Ghana Med J*, 2007; 41: 12-15.
- Sebanjo IO, Kazeem AO, Njokanma OF. *Helicobacter pylori* associated with breastfeeding, nutritional status and recurrent abdominal pain in healthy Nigerian children. *J Infect Dev Ctries* 2014; 8: 448-453
- Etukudo OM, Ikpeme EE, Ekanem EE. Seroepidemiology of *Helicobacter pylori* infection among children seen in a tertiary hospital in Uyo, southern Nigeria. *Pan Afr Med J* 2012; 12: 39-42
- Galloway JM, Gibson J, Dalrymple J. Endoscopy in primary care a survey of current practice. *Br J Gen Pract* 2002;52:536-538.
- Abbas S, Shaw S, Campbell D, et al. Outpatient upper gastrointestinal endoscopy: large, prospective study of the morbidity and mortality rate at a single endoscopy unit in England. *Dig Endosc* 2004;16: 113-116.
- Quine MA, Bell GD, McCloy RF, et al. Prospective audit of upper gastrointestinal endoscopy in two regions of England: safety, staffing, and sedation methods. *Gut* 1995;36:462-467.
- NCEPOD. Scoping our practice. The 2004 report of the national confidential enquiry into patient outcome and death. London: NCE-POD, 2004.
- Thomson M, Elawad M, Barth B, Seo JK, Vieira M: Worldwide strategy for implementation of paediatric endoscopy: Report of the FISPGHAN Working Group. *J Pediatr Gastroenterol Nutr* 2012, 55:636-639.
- Thomson M, Heuschkel R, Donaldson N, Murch S, Hinds R: Acquisition of competence in paediatric ileocolonoscopy with virtual endoscopy training. *J Pediatr Gastroenterol Nutr* 2006, 43:699-701.