

Adedoyin OT
Afolayan FM
Buhari MO
Abdulkadir MB
Ibrahim OR
Akintade OO
Abdualzeez TA

Acute glomerulonephritis mimicking nephrotic syndrome

DOI:<http://dx.doi.org/10.4314/njp.v43i2.6>

Accepted: 4th January 2016

Adedoyin OT (✉)
 Afolayan FM, Abdulkadir MB
 Ibrahim OR, Akintade OO
 Abdualzeez TA
 Department of Paediatrics and
 Child Health
 University of Ilorin Teaching Hospital,
 Ilorin, Kwara State, Nigeria
 Email: ooadedoyin@yahoo.com

Buhari MO
 Department of Pathology,
 University of Ilorin Teaching Hospital,
 Ilorin, Kwara State, Nigeria.²

Abstract: *Background:* Acute post infectious glomerulonephritis (APIGN) describes a wide range of glomerulonephritis characterized by an immunologic response of the kidney to varieties of infectious agent commonly bacteria. It is characterized by an abrupt onset of haematuria, moderate oedema, hypertension and proteinuria usually < 2g/dl. However, between 2013 and 2015, we managed two children who had histological diagnosis of post infectious glomerulonephritis but presented with full complement of features of nephrotic syndrome including nephrotic range proteinuria in addition to the features of nephritis.

Case reports: A 5year old boy and an 8 year old girl were admitted to our Paediatric Unit with history of generalized body swelling, reduction in the volume of urine and cough. There was no antecedent sorethroat or skin rash. At presentation, both patients had mild dyspnea, anasarca, massive ascitis, and hypertension

(130/80mmHg and 150/100mmHg respectively) both systolic and diastolic blood pressure were greater than 99 percentile. Laboratory investigations revealed massive proteinuria of 4+ and 3+ respectively, haematuria, hypoalbuminemia, and hyperlipidemia. The histology of their renal tissues revealed features in keeping with acute glomerulonephritis.

Conclusion: Acute glomerulonephritis may present with features of nephrotic syndrome including nephrotic range proteinuria. Hence in the event of the presentation of a mixed feature of nephrotic-nephritis as obtained in the case of these two children, management should first be in the line of AGN while awaiting the renal histology outcome before considering the commencement of steroid.

Keywords: Acute post infectious glomerulonephritis, post streptococcal glomerulonephritis, massive proteinuria.

Introduction

Acute post infectious glomerulonephritis (APIGN) describes a wide range of glomerulonephritis characterized by an immunologic response of the kidney to varieties of infectious agent commonly bacteria^{1,2,3}. It is characterized by intra glomerular inflammation with cellular proliferation from an immunologic response to bacteria, viruses and protozoa.² The most common form of APIGN is the post streptococcal glomerulonephritis (PSGN) caused by nephritogenic strains of *group A beta hemolytic streptococcus* infection of the throat and skin.^{3,4} It is an important cause of acute kidney injury in children. Though, the true incidence of APIGN is not known due to the frequency of subclinical form, it has

remained an important public health problem.³

The incidence of APIGN in the developing countries is on the increase but has however declined in the industrialized world. Globally, the incidence of acute PSGN was estimated at 472,000 cases per year, out of which 456,000 occurred in developing countries⁴. The incidence of PSGN in the less developed world was reported at 24.3 cases per 100,000 person/ year whereas in the industrialized countries, its estimated prevalence was 0.3 cases per 100,000 person/ year.⁵ Thus, it is a disease of underdeveloped and developing countries commonly seen in children under the age of 15.

The typical clinical presentation of PSGN which is a representative of a larger group of APIGN is an abrupt

onset of microscopic haematuria, oedema, hypertension, oliguria, azotemia, and proteinuria.⁴ The urinary excretion of protein varies widely in PSGN but the rate is generally *less* than 3g/ days which is what is found in nephrotic syndrome. The oedema in PSGN is due to retention of fluid and electrolyte (sodium).⁴ Unlike nephritic syndrome, nephrotic syndrome is characterized by massive proteinuria, hypoalbuminemia, hyperlipidemia and anasarca (generalized oedema).

However, there can be an atypical presentation of nephritic syndrome characterized by symptoms of both nephritic and nephrotic syndrome. When this occurs, the glomerular lesion is at the mesangium and the membrane.⁶ Patients with nephrotic range proteinuria in post streptococcal glomerulonephritis has poor prognosis and tend to develop hypertension and can also progress to chronic glomerulonephritis. We describe two children who had histological diagnosis of post infectious glomerulonephritis but with full complement of features of nephrotic syndrome including nephrotic range proteinuria in addition to features of nephritis.

Case report

Case 1

A 5 year old boy presented at the Emergency Paediatric Unit with a six day history of generalized oedema and a four day history of reduction in urinary output. There was progressive body swelling which initially started from the face and was described as being worse in the morning but disappears as the day goes by which later progressed to involve both legs and the abdomen and then became generalized. Four days after onset of body swelling, his parents noticed a reduction in urine production in both volume and frequency. There was no passage of coke colored or frothy urine and no prior history of a preceding sore throat or skin rash before onset of symptoms. There was history of occasional cough but no difficulty in breathing or orthopnea. No history of use of mercury containing soap, waddling in streams or recent blood transfusion. No family history of renal disease. Parents also attested to the use of herbal remedies. He was treated for malaria a month before symptoms. There was no history of headache, convulsion or loss of consciousness.

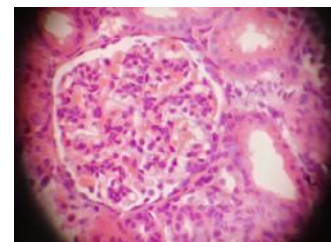
Physical examination revealed anasarca with platysma lock and mild respiratory distress evidenced by flaring of the alar nasi. He Weighed 21kg (expected 18kg), height: 104cm, heart rate 84/min, respiratory rate: 24cpm, blood pressure was 130/80 mmHg. There were wide spread basal crepitations bilaterally, breath sounds were normal. There was no added heart sound. The abdomen was uniformly distended with flank fullness with no organ enlargement. Moderate ascitis was demonstrable by shifting dullness and the abdominal girth was 63.8cm measured 14cm from xiphisternal junction. There was also scrotal edema. There was no neurological deficit.

The complete blood counts revealed moderate anaemia (PCV-33%) with reversal of differential. Urinalysis

showed massive proteinuria(4+), haematuria(3+). Serum creatinine was 57 μ mol/l. Lipid profile revealed hypercholesterolemia (7.1mmol/l) and hypertriglyceridaemia (2.2mmol/l). Serum albumin(18g/l) and protein (20g/l) were markedly reduced.

There was no bacteria growth in both throat and urine culture. He was managed as a case of nephritic-nephrotic syndrome and commenced on intravenous frusemide, ceftriaxone, nifedipine. Blood pressure had normalized by the fourth day on admission. There was resolution of the edema by the 8th day on admission and by day 12, proteinuria and haematuria were 1+ respectively. Renal biopsy revealed endocapillary proliferation with infiltration of neutrophils and mesangial cellular proliferation consistent with diffuse proliferative lesions highly suggestive of post-infectious glomerulonephritis (Figure 1).

Fig 1: Endocapillary proliferation with infiltration of neutrophils and mesangial cellular proliferation consistent with diffuse proliferative lesions highly suggestive of post-infectious glomerulonephritis (\times 400).



Case 2

An 8 year old girl presented with a seven day history of generalized body swelling, five day history of cough and a three day history of difficulty with breathing. The swelling started from the face and progressed to involve the lower limb and abdomen. Swelling was worse early in the morning and progressively resolved as the day went by. There was no antecedent history of sore throat or rash, though urine volume and frequency were reduced. There was no pain on micturition or passage of coke colored urine. No history of use of mercury containing soap, insect bite or ingestion of herbal remedies. Cough started two days after the onset of body swelling, was insidious in onset and non paroxysmal. It was productive of whitish sputum and not blood stained. Associated difficulty in breathing started a day after the onset of cough with worsening on lying supine. There was no cyanosis

Physical examination revealed anasarca and mild pallor (26%). She was in respiratory distress, respiratory rate; 42cpm with intercostal and subcostal recession. There was a reduced breath sound with bilateral coarse basal crepitations. Pulse rate; 122bpm, blood pressure was 150/100 mmHg. Abdomen was uniformly distended (girth-71 cm measured 15cm from the xiphisternum), The liver was enlarged measuring 8cm below right costal margin with a span of 16cm. There was massive ascitis demonstrable by fluid thrill. There was no neurological deficit.

Initial laboratory test included complete blood counts which reveal moderate anaemia(26%). Urinalysis showed massive proteinuria (3+), haematuria (1+).

Serum creatinine was 392 $\mu\text{mol/l}$, urea was 19.1 mmol/l , hypoalbuminemia (18g/l), serum cholesterol was 5.7 mmol/l , serum triglyceride was 2.1 mmol/l . A diagnosis of nephrotic syndrome complicated by acute renal failure with pulmonary oedema was made.

She was commenced on oxygen at 3Litre/ min, intravenous frusemide at 2mg/kg, then 1mg 8hrly. Intravenous ceftriaxone was administered. She was given a bolus of intravenous hydralazin followed by oral hydrochlorothiazide, methyl dopa and captopril. By second day on admission, respiratory distress had resolved, blood pressure was still elevated warranting another bolus of intravenous hydralazin.

Blood pressure remained between 140/110-120/90mmHg in the first week on admission before a significant improvement was made. She was maintained on the prescribed medication. She had progressive resolution over the following 14 days into admission; oedema and ascitis resolved, weight declined, urinary output was within 1.1- 2.5ml/kg/hr and proteinuria and haematuria were 1+ and 2+ respectively by the 12th day. Renal biopsy done 10 days into admission revealed features in keeping with diffuse proliferative lesions highly suggestive of post-infectious glomerulonephritis (Figure 1). Child recovered and was discharged for follow up in the clinic.

Discussion

The presence of the combination of features of nephrotic and nephritic syndrome results in a clinical impression of nephrotic-nephritic syndrome. However, in view of the presence of nephrotic syndrome, it was instructive to carry out a renal biopsy to delineate the histological type. Furthermore renal biopsy was necessitated to differentiate between AGN which would not require steroid and NS which requires the commencement of steroid to classify whether it was steroid responsive or resistant. In the two patients, while we were expecting a non-Minimal change NS such as focal segmental glomerular sclerosis (FSGS), membranoproliferative glomerulonephritis (MPGN) e.t.c we obtained a diffuse proliferative acute glomerulonephritis most probably post infectious.

The presence of features of haematuria, hypertension and indeed azotaemia in children with NS portends a poor prognosis as they will likely be non-MCNS. Hence extra care is deployed once nephrotic syndrome is accompanied by features of nephritic syndrome. The concomitant clinical presentation of these two cases was that of nephrotic syndrome with massive proteinu-

ria, hypercholesterolemia and hypoalbuminemia. However, the presence of hypertension, haematuria and oedema which are the three most important triad of PSGN makes it a mixed nephritic. The proteinuria and haematuria of nephrotic syndrome is due to break in the glomerular basement membranes, resulting from an inflammatory response due to an immunologic mechanism. Unlike nephritic syndrome, massive proteinuria is one of the most important findings in nephrotic syndrome and it is due to damage to the podocyte within the glomerular membrane, leading to loss of negative charge and thus increased permeability of the glomeruli. This leads to loss of albumin in urine, resulting in hypoalbuminemia cumulating into reduction in oncotic pressure and finally oedema. Massive proteinuria is a rare and atypical presentation in PSGN and when it occurs, it is associated with severe disease and poor prognosis. In PSGN, clinical recovery is the rule in 90% of cases. However with a finding of massive proteinuria, the course of the microscopic proteinuria is likely to be prolonged in atypical PSGN leading to chronic renal insufficiency. Thus early differentiation between a nephrotic-nephritic overlap and a typical nephritic syndrome using a renal biopsy as a tiebreaker is important because their management and prognosis are quite different. Though, renal biopsy is not often needed in PSGN, except in atypical presentation.

Most studies that described an overlap of nephrotic and nephritic syndrome were in adult population with a different etiology other than group A beta hemolytic streptococcus.⁷ Most importantly in resource poor countries where there are few facilities for renal biopsy, most patient with true PSGN who had atypical presentation tending towards a nephrotic syndrome might be treated as nephrotic using steroid which is clearly contraindicated in PSGN.

Conclusion

While the presence of a nephrotic picture in a PSGN is atypical, clinicians should not commence steroid in such mixed state until a renal biopsy has been carried out, hence a nephrotic-nephritic picture makes renal biopsy mandatory. On the other hand in resource poor setting where renal biopsy may be difficult to procure, such patients should be managed first as PSGN while watching the trend and progress for relapse which would further confirm nephrotic syndrome as recurrence is rare in PSGN or complete recovery if it is PSGN. In addition, follow up for the occurrence of persistent proteinuria, haematuria and hypertension will help prevent long term morbidity and mortality.

References

1. Moroni G, Ponticelli C. Acute post-infective glomerulonephritis. *Recenti Prog. Med.* 2003;94:395-398.
2. Stratta P, Musetti C, Barreca A, Mazzucco G. New trends of an old disease: The acute post infectious glomerulonephritis at the beginning of the new millenium. *J. Nephrol.* 2014;27(M):229-239.
3. Kanjanabuch T, Kittikowit W, Eiam-Ong S. An update on acute postinfectious glomerulonephritis worldwide. *Nat Rev Nephrol.* 2009;5:259-269.

-
4. Eison TM, Ault BH, Jones DP, Chesney RW, Wyatt RJ. Post-streptococcal acute glomerulonephritis in children: Clinical features and pathogenesis. *Pediatr. Nephrol.* 2011;26:165–180.
 5. Rodriguez-Iturbe B, Rodriguez-Iturbe B, Musser JM, Musser JM. The current state of poststreptococcal glomerulonephritis. *J Am Soc Nephrol.* 2008;19:1855–64.
 6. Alper C. The Kidney. In: Kumar V, Abbas A, Fausto N, Aster J, editors. *Robbins and Contrans Pathologic Basis of Disease*. Saunders Elsevier; 2012. p. 982–3.
 7. Velasquez TG, Barrios EJ, Botello CD. Nephrotic syndrome with a nephritic component associated with toxoplasmosis in an immunocompetent young man. *Colomb Med.* 2012;43:226–229.